




# Percutaneous sclerotherapy using polidocanol in the treatment of aneurysmal bone cysts of extremities – a report of 28 consecutive cases

Raj Kumar Harshwal , Kaushal Kishore Kumawat, Narender Saini,  
Manisha Sehrawat, Devi Sahay Meena

Department of Orthopedics, SMS Medical College, Jaipur, Rajasthan, India

## ABSTRACT

**Introduction and aim.** Aneurysmal bone cysts (ABC) are aggressive benign lesions with high rates of recurrence rendering its treatment uniquely challenging. We report the outcome in 28 consecutive patients of ABC of extremities treated with percutaneous sclerotherapy using 3% polidocanol over a period of 5 years.

**Material and methods.** In biopsy proven 28 ABC cases, Injection polidocanol 3% was used as sclerosing agent under fluoroscopy guidance. Injections were repeated at 6-week intervals till complete healing of cysts. Radiological and functional results were assessed by Rastogi et al. criteria, VAS score and Enneking scoring method.

**Results.** 25 out of 26 patients (89.28%) displayed good clinical response with an average 2.56 injections per patients. The mean follow-up period was 17.04±7.08 months. Reduction in cyst volume (mean 6.86±1.48 to 0.71±1.48.) and VAS score (mean 6.72±1.51 to 0.56±1.08) and improvement in Enneking score (17.35±3.14 to 28.92±1.35) at last follow up was significant. No recurrence was reported during the study period. Treatment failure, skin sclerosis and infection were reported in one case each.

**Conclusion.** sclerotherapy with polidocanol 3% for primary ABC is safe and effective alternate method with advantage of no surgical morbidity, having better functional score with lesser recurrence and minimal complications.

**Keywords.** aneurysmal bone cysts, Enneking score, polidocanol 3%, recurrence, sclerotherapy

## Introduction

Aneurysmal bone cyst (ABC) was first described by Jaffe and Liechtenstein in 1942.<sup>1</sup> The lesion can be described as an eccentric, expansile, lytic lesion with cortical thinning, and a subperiosteal thin shell of bone located in the metaphysis of long bones and the spine. It occurs in the age group of 3 to 40 years, constituting about 1% of benign bone tumors.<sup>2</sup> The clinical presentation of pain and swelling, with or without pathologic fracture, is characteristic of ABCs. The predictable treatment goals are to halt the progression of the lesion,

relieve pain, prevent pathological fractures and reduce recurrence rates.<sup>3</sup> To this end, various treatment modalities have been described, ranging from surgical procedures, selective artery embolization (SAE), heat-based ablations (microwave/radiofrequency/cryo-ablation), radiation to medical therapies.<sup>4-9</sup> Surgical treatment of ABC is associated with surgical morbidity, decreased range of motion and deformity due to potential physeal damage, along with a high recurrence rate of about 10% to 30%.<sup>10</sup> Recently, there has been a growing interest in less invasive approaches.

Corresponding author: Raj Kumar Harshwal, e-mail: [drrajharsh@gmail.com](mailto:drrajharsh@gmail.com)

Received: 18.07.2023 / Revised: 30.08.2023 / Accepted: 24.09.2023 / Published: 30.12.2023

Harshwal RK, Kumawat KK, Saini N, Sehrawat M, Meena DS. Percutaneous sclerotherapy using polidocanol in the treatment of aneurysmal bone cysts of extremities – a report of 28 consecutive cases. *Eur J Clin Exp Med*. 2023;21(4):840–848. doi: 10.15584/ejcem.2023.4.29.



Sclerotherapy is a newer modality that acts by causing damage to the endothelium of vessels and initiating a coagulation cascade that results in thrombosis and healing of the lesion.<sup>11,12</sup> Percutaneous sclerotherapy with polidocanol has been used in a few studies with promising results in terms of lesser recurrence and morbidity but safety and efficacy are still debated.<sup>10-14</sup>

### Aim

We report the outcomes in 28 consecutive patients with ABC of the extremities treated with percutaneous sclerotherapy using 3% polidocanol over a period of 5 years.

### Material and methods

Twenty eight patients of primary ABC of the extremities were treated with percutaneous sclerotherapy using 3% polidocanol between 2015 and 2020 at our tertiary level medical college center. Institutional ethics committee approval was obtained prior to the study's initiation (IEC NO. 1124/MC/EC/2015). All patients presenting with radiological evidence of primary ABC of the extremities at the orthopedics outpatient department (OPD) of the tertiary level medical college center underwent MRI and biopsy using the JAMSIDHI needle (J needle) no. 11, Aspiration and breaking of the septa were performed. A biopsy sample was taken from this aspirate and sent for histopathological confirmation.

A treatment holiday of 4 weeks was given to all patients after histopathological confirmation to allow for spontaneous healing of the lesion after bone puncture or trauma. During this 4-week period, patients were specifically instructed to note any increase in pain and swelling of the lesion. After four weeks, patients were followed up for clinical assessment of any change in pain intensity or size of swelling, and plain radiographs of the extremity were obtained to assess healing or progression of the lesion.

The approximate volume of the lesion was calculated using plain radiographs by multiplying the maximum length and breadth in the AP projection and the depth in the lateral projection. If, at the 4th week, the lesion did not heal or spontaneously reduce, then the patient was subjected to percutaneous injection of 3% polidocanol under fluoroscopy.

### *Technique of the polidocanol 3% injection application*

All the procedures were conducted in the orthopedic operating theater under the guidance of the senior author. Patients under 12 years old, were given general anesthesia, while those over 12 years old were treated under local or regional anesthesia depending on the extremity. C-arm fluoroscopy was used to guide the injection site. The lesion was punctured with a J needle no. 11 and the contents of the cyst were aspirated to ensure proper positioning. The aspiration of a significant

amount of blood from the ABC cavity was interpreted as a sign of remaining active disease. Before the injection of the sclerosant, Iohexol dye (7 mg/mL) in a 50 % dilution with normal saline (maximum 10 ml) was instilled into the lesion to identify the specific loculi to be injected especially in patients requiring multiple sitting. Prior to injecting the polidocanol, the drug was frothed using a 3-way cannula to reduce the chance of sclerosant spillage into soft tissue. Injection of Asklerol (polidocanol 3%, 60 mg/2 mL, Samarth Lifesciences Ltd.) was given at a ratio of 1 ml for each 1 cm<sup>3</sup> of the lesion, up to a maximum of 10 mL in a single session.<sup>13</sup> After the injection of the sclerosant, a 1 ml saline flush was used, and the needle end was plugged for 1 minute. A purse-string suture was applied when the J needle was inside the lesion, and it was tightened immediately after the removal of the needle to prevent spillage of the sclerosant agent around subcutaneous tissue and skin. Patients were reviewed after 7 days to monitor for local complications of sclerosant injection. Thereafter, patients were followed up every 6 weeks with new radiograph and to assess the reduction of cyst volume, signs of cortical sclerosis, and opacification of the cavity. Patients who showed poor progression or had patchy opacification (loculation) were reinjected at 6-week intervals.

Radiographic healing and satisfactory progression were defined by opacification of the lesion with an increase in cortical thickness. Treatment completion was defined as opacification of the lesion (or all loculi) such that no additional injection was needed. Recurrence was defined as the development of a fresh area of radiolucency in a previously opacified cyst (treatment completed), with or without an increase in the size of the lesion. Treatment failure was defined as a lesion that failed to show opacification either altogether or in part after three sequential injections or in which any new communicating lesion appeared during treatment.

Radiological assessment of the reduction in cyst volume was done according to the criteria by Rastogi et al., with grade I representing residual lesion <25% of the initial lesion, grade II for residual lesion 25% to 49%, grade III for residual lesion 50% to 74%, and grade IV for residual lesion 75% or more.<sup>13</sup> Clinical assessment of reduction in pain was performed using the visual analogue scale (VAS) score. Functional score was assessed using the Enneking functional scoring method.<sup>15</sup>

For statistical analysis, qualitative data (age, bone site) were presented as percentages and proportions. Quantitative data (cyst size, VAS score, etc.) were calculated as means and standard deviations. Paired t tests were used to compare differences in cyst size, VAS score, and final functional score before and after treatment within a group. Microsoft Excel and Primer software (McGraw-Hill Global Education Holdings, LLC, NY, USA) for the analysis.

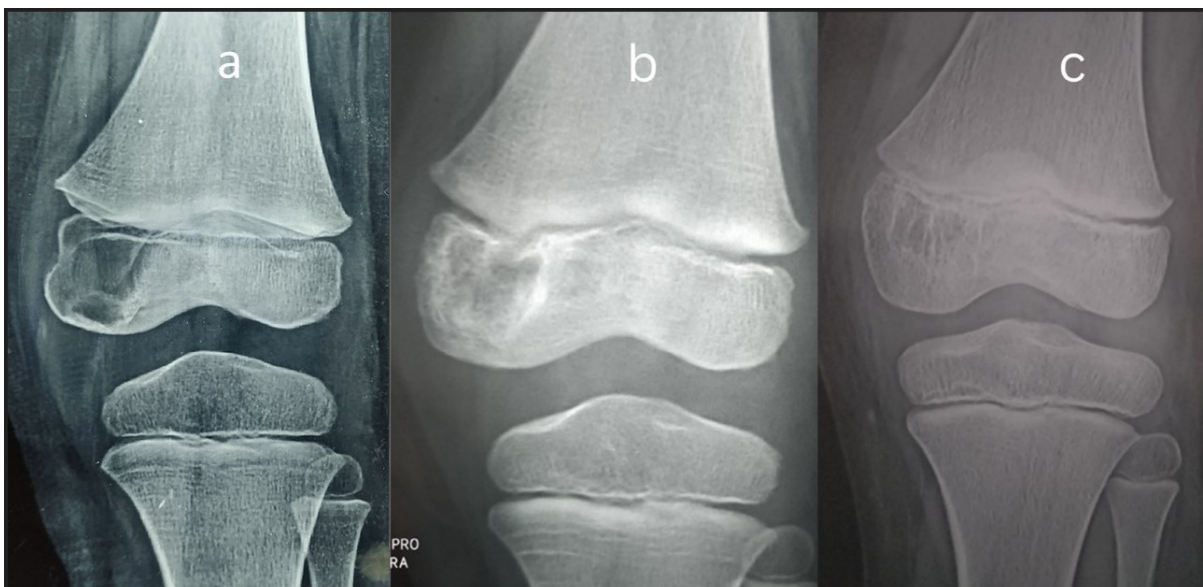
## Results

A total 28 biopsy proven patients with ABC were included in the study. The male to female ratio was 4:3, and the mean age at presentation was  $21.21 \pm 9$  years, ranging from 3 to 40 years. The maximum number of ABC lesions was located in the radius and tibia (6 each), followed by the fibula (4), humerus (3), femur (3), pelvis (2), 5<sup>th</sup> metacarpal (1), and calcaneum (1) (Table.1). The lesion was situated at the metaphysis in 22 cases, at epiphysis in one case (Fig. 1), and five had meta-diaphyseal extension. Three cases had taken tablet ibandronic acid 150mg monthly for three months as conservative treatment at a previous center. Sixteen cases were operated under local anesthesia while general and regional anesthesia were applied in 6 cases each (Table 2). Out of 28 cases, 26 were injected with 3% polidocanol intra-lesionally, and they were followed up every 6 weeks. In one case where the lesion was situated at the tibial metaphysis in a 7-year-old child, spontaneous resolution of the cyst occurred after the biopsy procedure. In another case, where ABC was located at the 4<sup>th</sup> metacarpal of the right hand, an open biopsy was previously performed at another center. When we tried to inject the dye for confirmation, it spilled into the soft tissue and the procedure had to be abandoned. Therefore, no sclerosant injection was given further in both patients, and they were excluded from the final functional results. The mean number of injections per patient applied was  $2.56 \pm 1.2$ , ranging from 1 to 6 (Table 3). The mean follow-up period was  $17.04 \pm 7.08$  months ranging 7 to 40 months. Radiological assessment of the reduction in the volume of the cyst was done according to Rastogi et al. criteria, we found that 88% of lesions (22 cases) fell into

grade 1, while 12 % (3 cases) fell in grade 2. No cases were found in grades 3 and grades 4. Significant reduction in the size of the cyst was achieved, with the mean prior to treatment decreasing from  $6.86 \pm 1.48$  to  $0.71 \pm 1.48$  after treatment (Table 4). There was also a significant reduction in the VAS score which decreased from a mean of  $6.72 \pm 1.51$  to  $0.56 \pm 1.08$  after treatment, and 80% were pain free at the final follow up. The improvement in the mean Enneking functional score was also significant going from  $17.35 \pm 3.14$  prior to treatment to  $28.92 \pm 1.35$  after treatment. In one case where the lesion was located at the distal radius, there was no reduction in the volume of the lesion and opacification after three consecutive injections. Therefore, sclerosant injections were stopped, and curettage and cancellous bone grafting were performed. The Lesion healed in 8 weeks and was termed a failure. No recurrence was reported during the study period. Two patients reported complications, including skin sclerosis due to sclerosant spillage and pus discharge at the injection site each.

**Table 1.** Distribution of the cases according to bone involved

Bone involved	Number	Percentage (%)
Femur	3	10.71
Tibia	6	21.43
Fibula	4	14.29
Humerus	3	10.71
Radius	6	21.43
Ulna	2	7.14
Pelvis	2	7.14
Metacarpal	1	3.57
Calcaneum	1	3.57
Total 28		



**Fig. 1.** Radiographs showing an ABC affecting the left distal femur in a 3-year-old female child contained entirely in epiphysis: (a) before treatment, (b) at completion of treatment, (c) at 39 months after sclerotherapy

**Table 2.** Distribution of cases according to type of anesthesia

Type of anesthesia	Number of patients	Percentage (%)
Local	16	57.14
Regional	6	21.42
General	6	21.42
Total	28	

**Table 3.** distribution of cases according to number of injections

No. of injections	No. of patients	Percentage %
0	1	4
1	4	16
2	8	32
3	7	28
4	4	16
6	1	4
Mean±SD	2.56±1.2	

**Table 4.** Paired sample t test showing results of sclerotherapy using 3% polidocanol

Variables	Pre op (mean)	Post op (at final follow-up) (mean)	Mean difference	p
VAS score	6.72±1.51	0.56±1.08	-6.16±1.99	<0.001
Volume of lesion	58.425±45 cc	1.974±3.54	56.45±44.99	<0.001
Enneking score	17.32±3.87	28.96±1.37	11.64±3.50	<0.001

**Discussion**

ABC is characterized an eccentric, expansile, osteolytic tumor like condition, located at the metaphysis of long bones and in the spine.<sup>2</sup> They are typically diagnosed during adolescence, and are equally rare in both sexes. Historically, ABCs were thought to result from increased venous pressure causing extravasation of cellular and blood contents into cyst-like voids in the bone. More recently, a genetic driver has been identified – a translocation induced up-regulation of the ubiquitin-specific protease USP6 (Tre2) gene – defining at least a subset of ABCs as primary neoplasm.<sup>16</sup>

Treatment options for ABC include surgical removal of the lesion, curettage with or without bone grafting, optional adjuvant therapy, endovascular treatment using selective arterial embolization, external-beam radiotherapy, and percutaneous directed therapies such as sclerotherapy, ablation, cementoplasty, and percutaneous injections of bisphosphonates or doxycycline.<sup>4,14,17,18</sup>

En bloc excision, is associated with the lowest rates of recurrence with 95–100 % localized control but it comes at the cost of high patient morbidity.<sup>4,17</sup> Simple Curettage of the lesion with or without bone grafting has been linked with high and sometime unacceptable recurrence rate of 18 to 59%<sup>18</sup>. Various adjuvants including cement, high-speed burr, argon beam, phenol, and cryotherapy have been developed to reduce recurrence, but they still result in an approximate 15% recurrence rate.<sup>8,10,19-22</sup>

Currently, there are no high-level controlled comparative studies regarding adjuvant efficacy, and the specific adjuvant strategy used varies based on the institution. Furthermore, surgical treatment of ABC is associated with surgical morbidity including postoperative pain, muscle weakness, decrease range of motion, limb length discrepancies and deformity due to potential physal damage.<sup>23</sup>

Selective artery embolization (SAE) of feeding blood vessels has been used for surgically inaccessible such as the pubic bone, sacrum, spine, and to reduce intraoperative blood loss during curettage. It has been proven to be an effective treatment method.<sup>24</sup> Rossi et. al. treated 36 ABC patients with selective arterial embolization using N-2-butyl cyanoacrylate. In their study a total of 55 procedures (1.5 procedures per patient) were performed on 36 patients.<sup>6</sup> Among these, 22 cases (61%) required only one embolization, 9 cases (25%) required two and the remaining 5 patients (14%) required three. Seven patients (19.4%) eventually required surgery during the study period. However the efficacy of this procedure is limited as not all ABCs have major feeding blood vessels, and the risk of ischemia in vital neural and visceral structures remains a major concern.<sup>13</sup>

Radiofrequency ablation (RFA), cryoablation, and microwave ablation have emerged as effective treatments for ABCs in various studies. RFA utilizes high-frequency electrical currents to heat and destroy tumor tissue, cryoablation employs extreme cold to freeze and kill abnormal cells while microwave ablation generates heat through microwave energy to coagulate the cystic mass. Each modality has its advantages but complications such as thermal injury to adjacent structures, nerve damage, and infection can arise from these procedures. Collaborative decision-making among orthopedic surgeons, interventional radiologists, and oncologists is crucial to tailor the treatment strategy based on the patient’s specific condition and anatomical considerations, ultimately leading to improved clinical outcomes.<sup>25</sup>

Radiotherapy has historically been used to treat ABCs primarily, as an adjuvant therapy in cases of recurrence, and in inoperable ABC lesions but Risk of malignant changes after radiotherapy and spinal deformity lead to abandoning this procedure.<sup>3,5</sup>

Denosumab has shown effectiveness as a rescue therapy for controlling ABCs but dangerous cases of hypercalcemia have been reported in children warranting its limited use to inoperable ABCs.<sup>26</sup> Systemic therapy with denosumab requires close observation to optimize treatment duration, a gradual discontinuation strategy and long-term monitoring for growth (deformities), serum calcium and mineral homeostasis.<sup>27</sup>

Sclerosants damage vascular endothelium, leading to in small vessels, and subsequent healing of the lesion.<sup>11</sup> Various sclerosing agent have been used to treat the ABCs including ethibloc, Methylprednisolone ace-

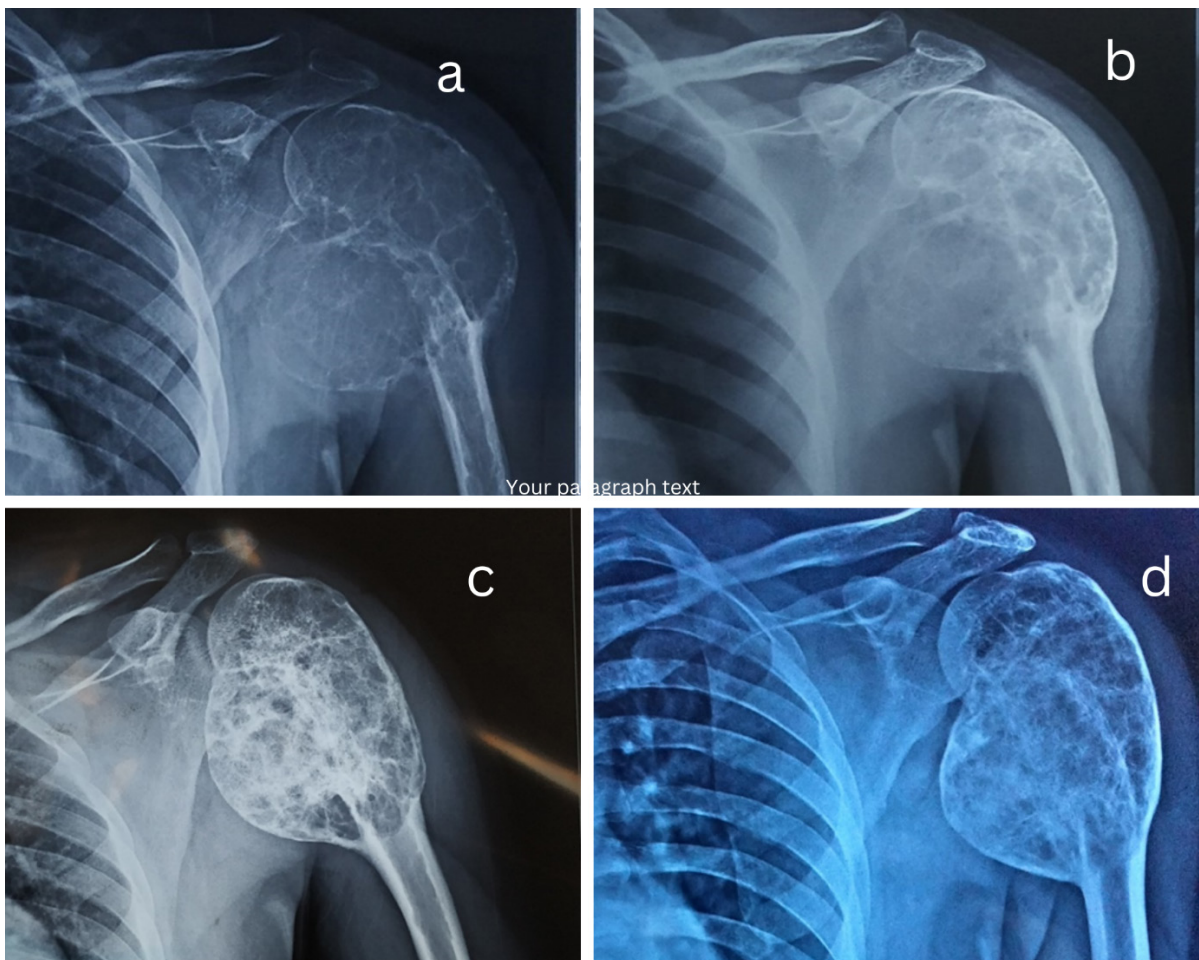
tate, calcitonin and radionuclides with healing rates of up to 92% and no recurrences.<sup>3,28</sup> However, a secondary procedure is required in 0% to 25% of patients. A meta-analysis by Cruz et al. reviewed 10 studies (294 patients) using Polidocanol, ethibloc, doxycycline, calcitonin, steroid or calcium sulfate as a sclerosant, reporting a recurrence-free survival of 94% at final follow-up (mean 41.1, range 23–58 months).<sup>24</sup> However, 68 out of 294 patients experienced complications including injection site induration, skin necrosis and fractures.

Polidocanol 3% injection has been used in the treatment of ABC in a few studies with good results. In our study we treated 25 ABC patients with polidocanol 3% injection and followed up until complete healing.<sup>10-14</sup>

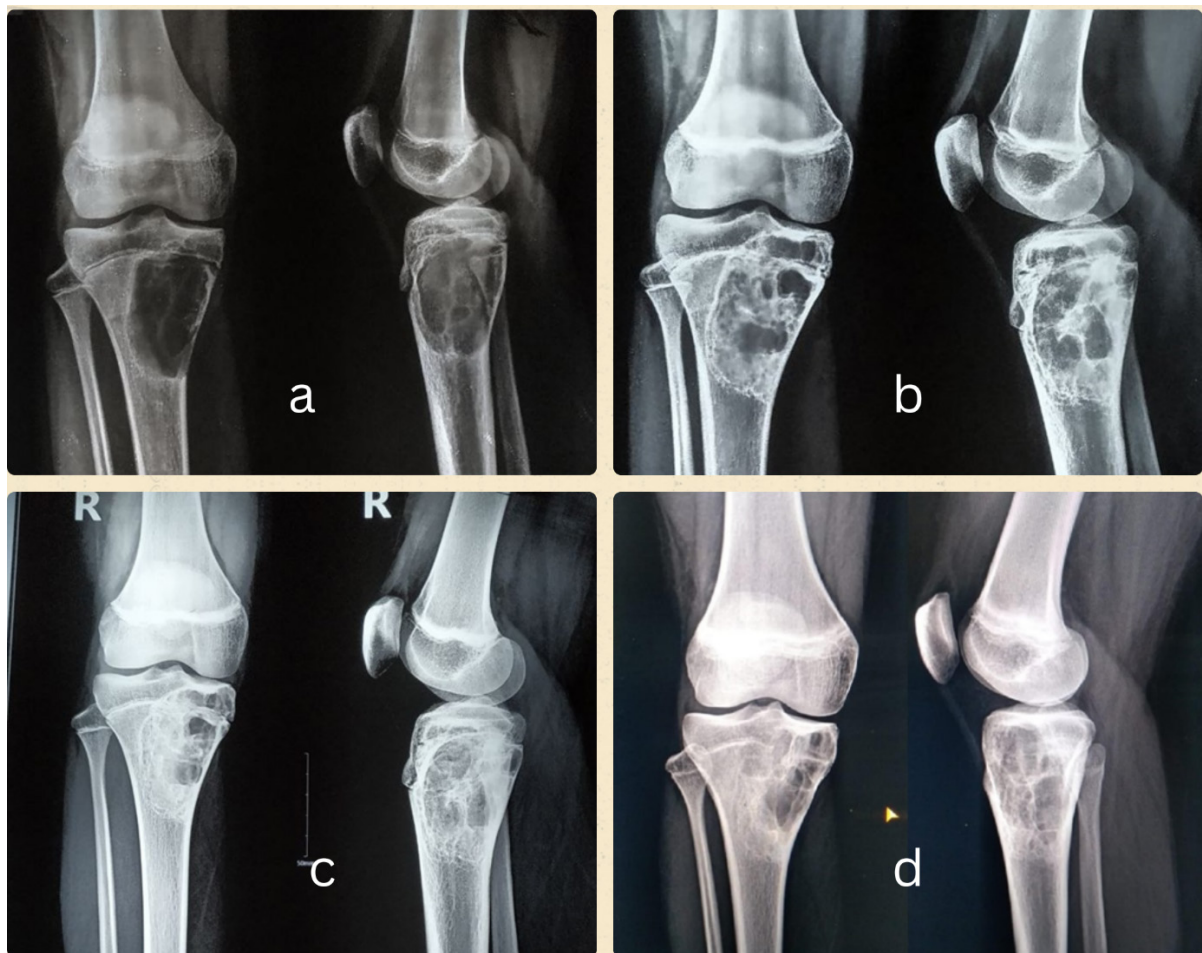
The mean age at presentation of ABC in our study was 21.21 years with a range from 3 to 40 years. Age distribution in our study remained almost equal in all age groups above 10 years. Children under 10 year had lower incidence of ABC, with the average age of patients being 21 years. These Findings are well consistent with studies conducted by Rastogi et al. and Varshney et al.<sup>13,14</sup>

Mascard et al. conducted a study and reported that ABCs are more commonly diagnosed in long bones in the (67%) than spine (15%) and pelvis (9 %).<sup>29</sup> In long bones, the tibia constitutes the most common site (40%), followed by the humerus (15 %) and femur (13%). Lower limbs are commonly affected (67%) than upper limb (20%). These findings are well correlated with our study, where we found that the incidence of ABC was more common in the lower limb (50%) followed by the upper limb (39%) and pelvis (7%). In our study the tibia and radius had an equal incidence of ABC (each 21%).

ABCs most commonly occur in the metaphyseal region of long bones. With time, large cysts may involve the diaphysis and become meta-diaphyseal (Fig. 2). Although epiphyseal extension has been reported in association with metaphyseal ABC (Fig. 3), Chan et al. found primary ABC entirely contained within the epiphysis which is a rare occurrence.<sup>30</sup> In our study, one patient aged 3 years had an ABC completely within the epiphysis of the distal femur (Fig.1). For this patient, polidocanol 3% was injected through a trans-epiphyse-



**Fig. 2.** Radiographs showing an ABC affecting the proximal humerus of the left side in a 25-year-old male with meta-diaphyseal extension: (a) before treatment, (b) An AP radiograph taken after two injections of polidocanol shows an unopacified loculation in the medial part of the lesion, (c) radiograph was obtained at completion of treatment after three injections, (d) AP and lateral view radiographs showing the lesion at 40 months with remodelling of the lesion



**Fig. 3.** Radiographs showing an ABC affecting the right proximal tibia metaphysis with epiphyseal extension in an 11-year-old female child: (a) before treatment, (b) after first polidocanol injection, (c) after second polidocanol injection at completion of treatment, (d) at 36 months after sclerotherapy

al route parallel to the physal plate. We took great care to ensure that there was no damage to the physal plate during the procedure. A single injection of sclerosant healed the lesion and there was no reported deformity or morbidity at the surgical site during the final follow up (39 months). This case highlights the importance of sclerotherapy in avoiding the morbidity associated with large surgical procedures and resulting epiphyseal damage and associated deformities. To the best of our knowledge, we did not find any previously reported cases of epiphyseal ABC treated with sclerotherapy in the literature

Reddy et al. introduced the concept of limited curettage using a J needle and a pituitary rongeur at the time of ABC biopsy and termed it *curopsy*.<sup>31</sup> They reported healing of lesion in 83 out of 102 cases (81%). In our study we also employed septal breaking with a J needle during simultaneous aspiration of blood. Only one case exhibited cyst consolidation and obliteration at 4 weeks, while the remaining 26 cases did not show any improvement with *curopsy* alone and leading them to be subjected to sclerosant treatment.

In a review of 72 ABC patients treated with polidocanol 3%, Rastogi et al. reported a clinical response rate of 84.5 % with an average of three injections per patient.<sup>13</sup> In a randomized trial, Varshney et al. compared polidocanol sclerotherapy with curettage, high-speed burr, and bone graft.<sup>14</sup> Polidocanol exhibited a healing rate of 93.3% compared to 84.8 % for curettage, with a mean of 2.3 injections per patient. In our study, 25 out of 26 patients (89.28%) completed treatment with polidocanol injection and displayed a good clinical response with an average of 2.56 injections per patient. 14% of patients achieved complete healing with a single injection only. These results underline the efficacy of polidocanol injection in cavity healing. The maximum number of injections required was six in a case where ABC was situated at the distal metaphysis of the femur. In this patient, even after consecutive two injections, the cyst volume did not reduce. Although the cyst was not large compared to others, it was situated at supracondylar level. Initially, this case was attempted without radio-opaque dye confirmation. Subsequent four injections were administered by the senior author under C-ARM guid-

ance after dye confirmation, led to cavity healing. The use of Iohexol dye enabled precise polidocanol instillation in the remaining cavity that resulting in healing.

Polidocanol injection proved excellent in radiological regressing the cavity. In 22 cases (88%), cavity size reduced to <25 % (grade 1), and in 3 cases, the cavity size reduced to <50% (grade 2) on final follow up. a study by Rastogi et al., showed 66% cases achieving grade 1 healing, 30% grade 2 and 28% grade 3.<sup>13</sup> The mean Enneking score prior to treatment was  $17.35 \pm 3.74$ , significantly increased to  $28.92 \pm 1.35$  after the final follow up. The improvement in functional score was associated with a reduction in lesion volume and decreased in pain. At the final follow up 80% of cases were pain-free. There was also a significant reduction in mean VAS score (from mean  $6.72 \pm 1.51$  to  $0.56 \pm 1.08$ ). In one case, after three continuous injections, the cyst did not show any reduction in volume or opacification. Therefore, it was deemed as failure. We utilized Iohexol 7mg/ml dye during sclerosant injection to confirm the exact site and ensured septa in every session, covering the entire cyst with sclerosing agent. This precise approach helped localize the cyst and sclerosant instillation, contributing to almost complete cavity resolution and excellent outcomes. This contributed to a higher number of pain-free patients and better functional scores at final follow-up.

Cornelis et al. reported varying degrees of lesion ossification and near-universal pain relief following bisphosphonate treatment for symptomatic, inoperable benign bone tumors including ABCs.<sup>9</sup> In our study, 3 out of 26 patients received bisphosphonate (Ibandronic acid 150 mg) 3 to 5 months prior to treatment. All three patients had received 2, 1, and 2 doses of polidocanol 3% respectively (average 1.7 doses, compared to 2.56 in the study), achieving complete cyst resolution and excellent functional scores at the final follow-up. Bisphosphonates are potent anti-resorptive agents that attach to hydroxyapatite sites on bone surfaces, particularly those undergoing active resorption. This inhibits osteoclast activity, preventing bone resorption and promoting osteoclast apoptosis. The anti-resorptive property may have contributed alongside polidocanol injection, leading to fewer injections and improved functional scores. This finding requires confirmation through further research.

Curettage of the lesion with or without bone grafting has been associated with a high and sometimes unacceptable recurrence rate ranging from 18% to 59%.<sup>3,7,10</sup> Other studies conducted by Varshney et al. (4.44%) and Rastogi et al. (2.8%) also demonstrated very low recurrence rates (4.44% and 2.8% respectively) when using polidocanol (Table 5).<sup>13,14</sup>

In our study, 57% of cases received polidocanol 3% injections under local anesthesia, well-tolerated, and were discharged on the same day after 3 hours of observation. General anesthesia was administered to only six

children. This suggests that sclerotherapy is an excellent outpatient procedure, resulting in shorter hospital stays and minimal anesthesia-related complications.

**Table 5.** Results of treatment of ABC with sclerotherapy

Sr. no.	Study	Number of cysts	Average injection per patient	Recurrence rate	Failure rate	Complications
1	Rastogi et al. 2006	72	3	2	–	induration at the site of injection (18 cases), hypopigmentation (3), local inflammatory reaction (1), and an episode of dizziness (1)
2	Varshney et al. (2010)	47	2.3	2	3	local induration (37) hypopigmentation at the injection site (11), and dizziness episode (one patient)
3	Deventer et al. (2021)	32	5.7	0	10	Healing disorder (2 cases)
4	Puthoor et al. (2021)	34	1.09	0	–	Ulcerations (1) and hypopigmentation (1)
5	Rai et al. (2022)	43	3.11	5	–	Induration of skin (7), hypopigmentation (4)
6	Our study	28	2.5	0	1	Superficial infection (1) and induration (1)

Sclerotherapy should not be performed in cases where previous open biopsy or surgery has been conducted, as spillage of the sclerosant could harm adjacent neurovascular structures and soft tissue. In our study one case reported skin necrosis due to sclerosant spillage, but skin sclerosis healed within 2 weeks with the application of local antibiotics and silver sulfadiazine ointment. Another case exhibited swelling and discharge one week after the second injection. We had to debride the lesion and administer IV antibiotics for 2 weeks; the cyst healed after 2 polidocanol injections. By the final follow-up, the infection had subsided, and no patients reported recurrence. We did not observe any complications such as hypopigmentation, allergies, or episodes of dizziness during treatment in any of the patients.

The major limitations of our study include the small number of patients, a relatively short follow-up period, the absence of a comparative group for result comparison, and limited statistical data for analysis.

## Conclusion

These preliminary results indicate that sclerotherapy with 3% polidocanol is safe, effective, and associated with fewer major surgical complications, yielding a better functional score and a lower recurrence rate. The procedure can be planned as a daycare procedure using local anesthesia in adults and mild sedation in pediatric patients.

## Declaration

### Funding

The authors did not receive grants or outside funding in support of their research for or preparation of this manuscript. They did not receive payments or other benefits or a commitment or agreement to provide such benefits from a commercial entity.

### Author contributions

Conceptualization, R.K.H. and D.S.M.; Methodology, R.K.H. and K.K.K.; Software, M.S.; Validation, R.K.H., K.K.K. and D.S.M.; Formal Analysis, N.S. and M.S.; Investigation, N.S. and M.S.; Resources, R.K.H.; Data Curation, R.K.H. and K.K.K.; Writing – Original Draft Preparation, R.K.H. and M.S.; Writing – Review & Editing, N.S. and D.S.M.; Visualization, M.S.; Supervision, R.K.H.; Project Administration, R.K.H.; Funding Acquisition, D.S.M.

### Conflicts of interest

The authors declare that they have no conflicts of interest

### Data availability

The datasets generated during and/or analyzed during the current study are available from the corresponding author on reasonable request.

### Ethics approval

The protocol was approved by the institutional Ethics Committee (SMS Medical College Jaipur (IEC NO. 1124/MC/EC/2015)).

## Reference

- Jaffe HL, Lichtenstein L. Solitary unicameral bone cyst with emphasis on the roentgen picture, the pathologic appearance and the pathogenesis. *Arch Surg.* 1942;44:1004-1025.
- Deventer N, Deventer N, Gosheger G, et al. Current strategies for the treatment of solitary and aneurysmal bone cysts: a review of the literature. *J Bone Oncol.* 2021;30:100384. doi: 10.1016/j.jbo.2021.100384
- Park HY, Yang SK, Sheppard WL, et al. Current management of aneurysmal bone cysts. *Curr Rev Musculoskelet Med.* 2016;9(4):435-444. doi: 10.1007/s12178-016-9371-6
- Can Celebioglu E, Onur Karaca M, Basarir K, Yusuf Yildiz H, Bilgic S. Selective Arterial Embolization (SAE) in Aneurysmal Bone Cyst (ABC). *Annals of Medical Research.* 2021;28(4):0743-0746.
- Feigenberg SJ, Marcus RB Jr, Zlotecki RA, Scarborough MT, Berrey BH, Enneking WF. Megavoltage radiotherapy for aneurysmal bone cysts. *Int J Radiat Oncol Biol Phys.* 2001;49(5):1243-1247. doi: 10.1016/s0360-3016(00)01462-0
- Rossi G, Rimondi E, Bartalena T, et al. Selective arterial embolization of 36 aneurysmal bone cysts of the skeleton with N-2-butyl cyanoacrylate. *Skeletal Radiol.* 2010;39(2):161-167. doi: 10.1007/s00256-009-0757-z
- Dormans JP, Hanna BG, Johnston DR, Khurana JS. Surgical treatment and recurrence rate of aneurysmal bone cysts in children. *Clin Orthop Relat Res.* 2004;(421):205-211. doi: 10.1097/01.blo.0000126336.46604.e1
- Steffner RJ, Liao C, Stacy G, Atanda A, Attar S, Avedian R, Peabody TD. Factors associated with recurrence of primary aneurysmal bone cysts: is argon beam coagulation an effective adjuvant treatment? *J Bone Joint Surg Am.* 2011;93(21):e1221-e1229. doi: 10.2106/JBJS.J.01067
- Cornelis F, Truchetet ME, Amoretti N, et al. Bisphosphonate therapy for unresectable symptomatic benign bone tumors: a long-term prospective study of tolerance and efficacy. *Bone.* 2014;58:11-16. doi: 10.1016/j.bone.2013.10.004
- Puthoor D, Francis L, Ismail R. Is sclerotherapy with polidocanol a better treatment option for aneurysmal bone cyst compared to conventional curettage and bone grafting? *J Orthop.* 2021;25:265-270. doi: 10.1016/j.jor.2021.05.020
- Deventer N, Schulze M, Gosheger G, de Vaal M, Deventer N. Primary Aneurysmal Bone Cyst and Its Recent Treatment Options: A Comparative Review of 74 Cases. *Cancers (Basel).* 2021;13(10):2362. doi: 10.3390/cancers13102362
- Rai AK, Rathod TN, Bansal D, et al. Clinicoradiological outcome of percutaneous intralesional polidocanol in Aneurysmal Bone Cysts: A prospective study of 43 patients in a single tertiary care centre. *J Orthop.* 2022;32:72-77. doi: 10.1016/j.jor.2022.05.010
- Rastogi S, Varshney MK, Trikha V, Khan SA, Choudhury B, Safaya R. Treatment of aneurysmal bone cysts with percutaneous sclerotherapy using polidocanol. A review of 72 cases with long-term follow-up. *J Bone Joint Surg Br.* 2006;88(9):1212-1216. doi: 10.1302/0301-620X.88B9.17829
- Varshney MK, Rastogi S, Khan SA, Trikha V. Is sclerotherapy better than intralesional excision for treating aneurysmal bone cysts? *Clin Orthop Relat Res.* 2010;468(6):1649-1659. doi: 10.1007/s11999-009-1144-8
- Enneking WF, Dunham W, Gebhardt MC, Malawar M, Pritchard DJ. A system for the functional evaluation of reconstructive procedures after surgical treatment of tumors of the musculoskeletal system. *Clin Orthop Relat Res.* 1993;(286):241-246.
- Legrand M, Jourdan ML, Tallet A, et al. Novel partners of USP6 gene in a spectrum of bone and soft tissue lesions. *Virchows Arch.* 2021;479(1):147-156. doi: 10.1007/s00428-021-03047-z
- Flont P, Kolacinska-Flont M, Niedzielski K. A comparison of cyst wall curettage and en bloc excision in the treatment of aneurysmal bone cysts. *World J Surg Oncol.* 2013;11:109. doi: 10.1186/1477-7819-11-109
- Döring K, Puchner S, Vertesich K, et al. Results in the surgical treatment of aneurysmal bone cysts - A re-



- trospective data analysis. *Orthop Traumatol Surg Res.* 2022;108(4):103095. doi: 10.1016/j.otsr.2021.103095
19. Tsoumakidou G, Too CW, Garnon J, Steib JP, Gangi A. Treatment of a spinal aneurysmal bone cyst using combined image-guided cryoablation and cementoplasty. *Skeletal Radiol.* 2015;44(2):285-289. doi: 10.1007/s00256-014-1967-6
  20. Keçeci B, Küçük L, Isayev A, Sabah D. Effect of adjuvant therapies on recurrence in aneurysmal bone cysts. *Acta Orthop Traumatol Turc.* 2014;48(5):500-506. doi: 10.3944/AOTT.2014.14.0020
  21. Liu X, Han SB, Si G, et al. Percutaneous albumin/doxycycline injection versus open surgery for aneurysmal bone cysts in the mobile spine. *Eur Spine J.* 2019;28(6):1529-1536. doi: 10.1007/s00586-018-5836-1
  22. Cummings JE, Smith RA, Heck RK Jr. Argon beam coagulation as adjuvant treatment after curettage of aneurysmal bone cysts: a preliminary study. *Clin Orthop Relat Res.* 2010;468(1):231-237. doi: 10.1007/s11999-009-0914-7
  23. Shiels WE 2nd, Beebe AC, Mayerson JL. Percutaneous Doxycycline Treatment of Juxtaphyseal Aneurysmal Bone Cysts. *J Pediatr Orthop.* 2016;36(2):205-212. doi: 10.1097/BPO.0000000000000413
  24. Cruz GS, Cuevas-Suárez CE, Saavedra JPA, Giorgis R, Teixeira MRK, Muniz FWMG. Percutaneous treatments of primary aneurysmal bone cysts: systematic review and meta-analysis. *Eur J Orthop Surg Traumatol.* 2021;31(7):1287-1295. doi: 10.1007/s00590-021-02893-6
  25. Bavan L, Wijendra A, Kothari A. Efficacy of treatment interventions for primary aneurysmal bone cysts: a systematic review. *Bone Jt Open.* 2021;2(2):125-133. doi: 10.1302/2633-1462.22.BJO-2020-0168
  26. Maximen J, Robin F, Tronchot A, Rossetti A, Ropars M, Guggenbuhl P. Denosumab in the management of Aneurysmal bone cyst. *Joint Bone Spine.* 2022;89(1):105260. doi: 10.1016/j.jbspin.2021.105260
  27. Deodati A, Fintini D, Levtchenko E, et al. Mechanisms of acute hypercalcemia in pediatric patients following the interruption of Denosumab. *J Endocrinol Invest.* 2022;45(1):159-166. doi: 10.1007/s40618-021-01630-4
  28. Adamsbaum C, Mascard E, Guinebretière JM, Kalifa G, Dubousset J. Intralesional Ethibloc injections in primary aneurysmal bone cysts: an efficient and safe treatment. *Skeletal Radiol.* 2003;32(10):559-566. doi: 10.1007/s00256-003-0653-x
  29. Mascard E, Gomez-Brouchet A, Lambot K. Bone cysts: unicameral and aneurysmal bone cyst. *Orthop Traumatol Surg Res.* 2015;101(1):119-127. doi: 10.1016/j.otsr.2014.06.031
  30. Chan G, Arkader A, Kleposki R, Dormans JP. Case report: primary aneurysmal bone cyst of the epiphysis. *Clin Orthop Relat Res.* 2010;468(4):1168-1172. doi: 10.1007/s11999-010-1228-5
  31. Reddy KI, Sinnaeve F, Gaston CL, Grimer RJ, Carter SR. Aneurysmal bone cysts: do simple treatments work? *Clin Orthop Relat Res.* 2014;472(6):1901-1910. doi: 10.1007/s11999-014-3513-1