



CASUISTIC PAPER

Abhishek Bhardwaj ^{1(AC)}, Sumeet Angral ^{1(BF)}, Sharath Chandra ^{1(G)},
Manu Malhotra ^{1(D)}, Madhu Priya ^{1(G)}, Saurabh Varshney ^{1(D)}, Arpana Singh ^{2(B)}, Ritu Raj ^{1,3(F)}

Parotid pilomatrixoma: Diagnostic trap and management dilemma

¹ Department of Otorhinolaryngology & Head-Neck Surgery, All India Institute of Medical Sciences, Rishikesh, India

² Department of Microbiology, All India Institute of Medical Sciences, Rishikesh, India

³ Department of Medicine, All India Institute of Medical Sciences, Rishikesh, India

Abstract

Introduction. Pilomatrixoma is a benign cutaneous adnexal neoplasm originating from the matrix cells of the hair follicles. Usually a slow growing and painless lesion, it must be considered in differential diagnosis of a preauricular swelling. Rapidly progressive lesion with skin fixity and missed subtle cytological features may lead to a misdiagnosis of parotid neoplasm resulting in management dilemma.

Aim. This report emphasizes consideration of pilomatrixoma as a differential diagnosis in a similar clinical scenario, the role of frozen section during surgery and fascia lata interposition to prevent Frey's syndrome. A brief review of literature is presented.

Description of the case. We present a similar dilemmatic case of a 19 years old male with preauricular swelling. Based on cytology and image findings, a diagnosis of parotid neoplasm with possible malignancy was made. Surgical exploration revealed primarily a subcutaneous lesion with partial attachment to superficial surface of parotid. Lesion was excised with a cuff of normal parotid tissue. Frozen section confirmed it to be a nonmalignant lesion with possibility of pilomatrixoma. Fascia lata was interposed between parotid and thin skin flap to avoid gustatory sweating. Patient is on follow up for 6 months without recurrence or any complication.

Conclusion. Pilomatrixomas can be misdiagnosed in case of lesions in subcutaneous plane in parotid region. In such cases, the differential diagnosis should include tumor and non-tumor lesions of skin and parotid gland. Importance of frozen section should also be kept in mind and the pathologist should be engaged at the time of surgical excision of the tumor. Interposition of soft tissue between parotid and thin skin flap helps prevent gustatory sweating in such cases. A high index of suspicion is needed for proper diagnosis and management of these lesions.

Keywords. parotid gland, parotid neoplasms, pilomatrixoma

Corresponding author: Sumeet Angral, e-mail: anralsumeet@gmail.com

Participation of co-authors: A – Author of the concept and objectives of paper; B – collection of data; C – implementation of research; D – elaborate, analysis and interpretation of data; E – statistical analysis; F – preparation of a manuscript; G – working out the literature; H – obtaining funds

Received: 3.10.2019 | Accepted: 13.01.2020

Publication date: March 2020

Introduction

Pilomatrixomas are the benign skin tumors which arise from the matrix cells of hair follicles. Synonyms: pilomatricoma, calcifying epitheloma of Malherbe.¹ Pilomatrixoma is a rare adnexal neoplasm of children and young adults first described in 1880. It presents clinically as a solitary lesion especially in head & neck region and upper extremities.² Pilomatrixoma are slow growing tumors with size ranging between 0.5 to 3 cm, the larger versions known as giant tumor (max diameter = 5 cm). These tumors have good prognosis however some become locally aggressive and also have tendency to reoccur, while others have potential to transform to pilomatrix carcinoma.^{3,4} Surgical excision is the treatment of choice.⁵

Aim

This report emphasizes consideration of pilomatrixoma as a differential diagnosis in a similar clinical scenario, role of frozen section during surgery and fascia lata interposition to prevent Frey's syndrome. A brief review of literature is presented.

Description of the case

We present a dilemmatic case of 19-year-old male patient who presented to our hospital with slow growing and painless swelling over right preauricular region for 9 months. Clinical evaluation revealed a 1.5cm × 1cm firm, non-fluctuating, non-tender, non-pulsatile swelling over right side preauricular region 1.5cm below the right zygoma. Skin overlying the swelling was non-

pinchable with no discharge or sinus. Swelling was mobile in all directions.

USG of the swelling showed a well-defined heterogeneously hypoechoic lesion measuring 1.2cm × 0.9 cm in the subcutaneous planes of right preauricular region (fig 1). Contrast MRI showed well defined lesion measuring 1.4 cm × 1 cm in subcutaneous plane in superficial lobe of right parotid gland with indistinct fat planes. Post contrast scan showed mild peripheral and central variegated enhancement (fig 2). FNAC showed features suggestive of possible malignancy. General examination as well as systemic examination of the patient did not reveal any co-existent anomaly. Since the diagnosis was uncertain in this particular scenario, right superficial parotidectomy with intraoperative frozen section analysis to assess the malignant status of the tumor was planned. Modified Blair's incision was given. Superficial musculoaponeurotic system (SMAS) flap was elevated to expose parotid. Over the lesion, only skin flap could be elevated. Lesion was attached to lateral aspect of superficial lobe but did not seem to arise from it. Hence, it was excised with a surrounding cuff of normal parotid tissue. Frozen section was suggestive of a nonmalignant lesion with possibility of pilomatrixoma (fig 3). Initial decision of parotidectomy was withheld. Tensor fascia lata was interpositioned between parotid and thin skin flap to avoid gustatory sweating. Peri and post-operative period were uneventful.

Histopathology report showed irregular islands of epithelial cells in a characteristic organization with a bi-

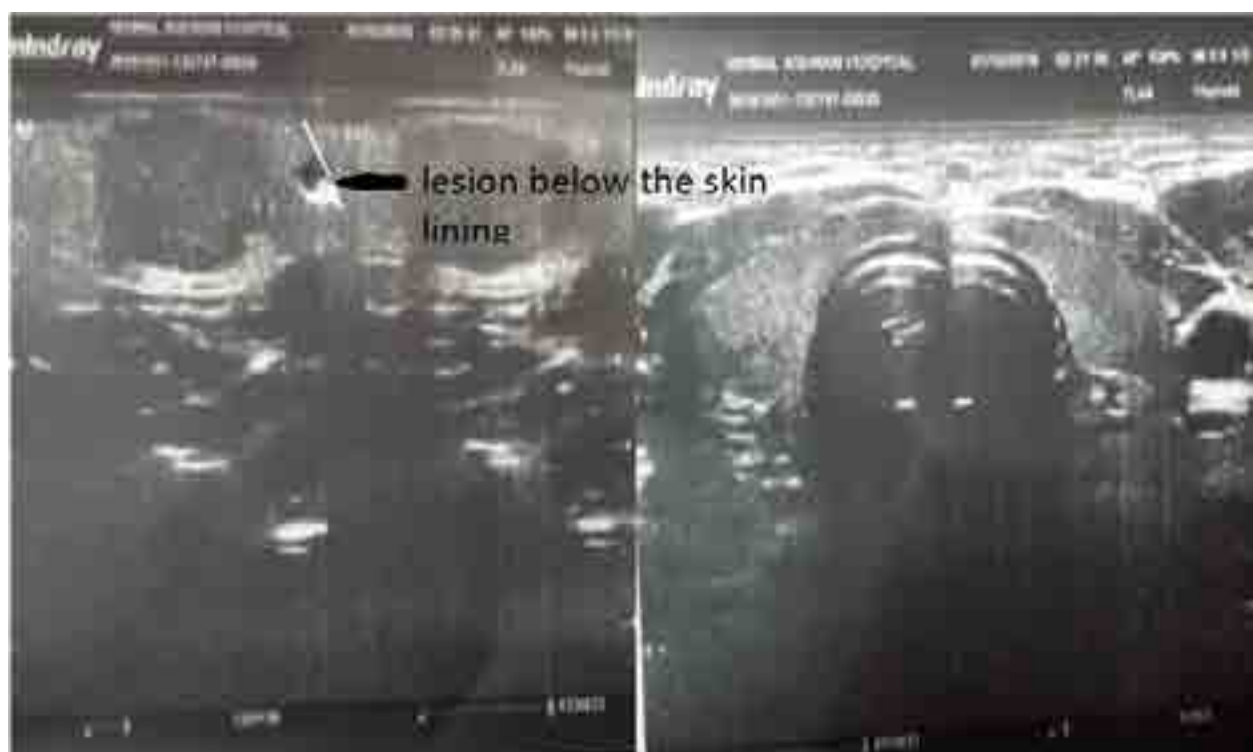

Fig. 1. USG of the swelling

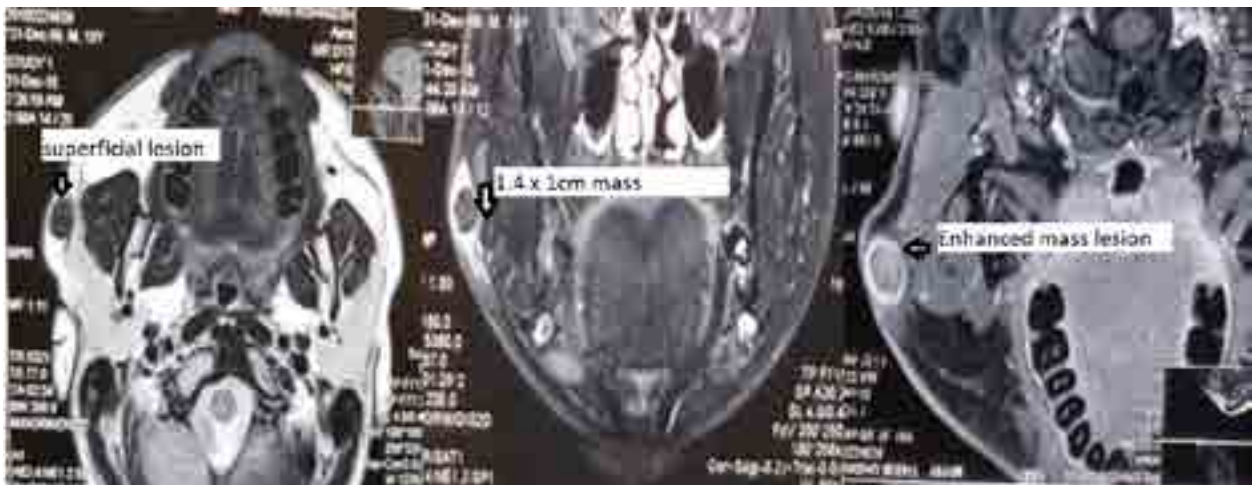

Fig. 2. Post contrast scan

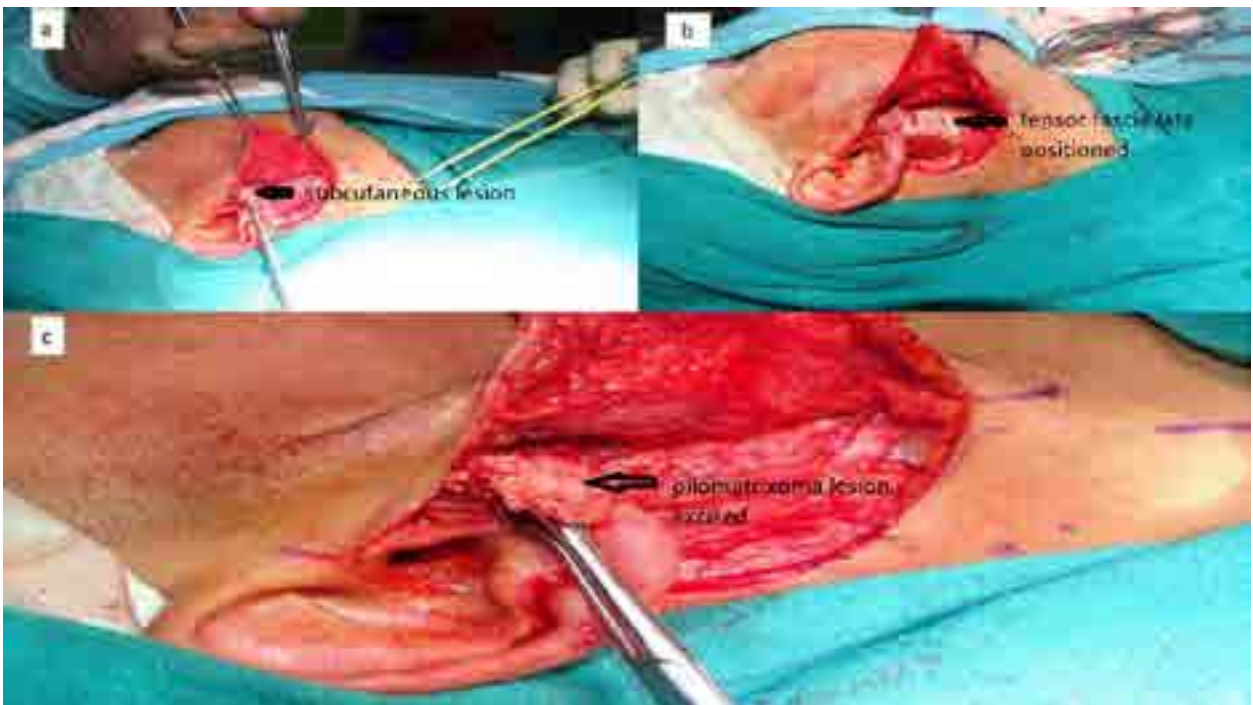


Fig. 3. Frozen section was suggestive of a nonmalignant lesion

phasic architecture composed of central ghost cells and varying amounts of basaloid cells in the periphery suggestive of pilomatrixoma (fig 4). Ghost cells are basically an enlarged epithelial eosinophilic cell which had shed their nucleus and contain only cytoplasm.

A final diagnosis of right parotid region pilomatrixoma based on HPE report was made. The patient is on regular follow up for past 8 months and there is no feature suggestive of loco regional recurrence.

Discussion

Pilomatrixoma originates from epidermal basal layer from stem cells that can differentiate as hair matrix cells.⁶ The published data indicates the incidence range

between 0.001% to 0.0031% from all dermatological histology specimens.⁷ Pilomatrixoma is the most common benign skin tumor of pediatric age group accounting for 20% of skin appendages tumor in most casuistries.⁸ Various studies show a bimodal age distribution for this tumor with highest incidence during the 1st and 2nd decade of life and a second lower peak between the age group of 50-65 years of age.⁹⁻¹¹ These tumors had a female preponderance with a female to male ratio ranging from 0.43:1 to 2.45:1.^{10,11} Our patient is a male who developed the lesion at an age of about 18 years.

Pilomatrixoma has a propensity to develop in head and neck regions with head as the more frequently involved region. In the head most common subsite being

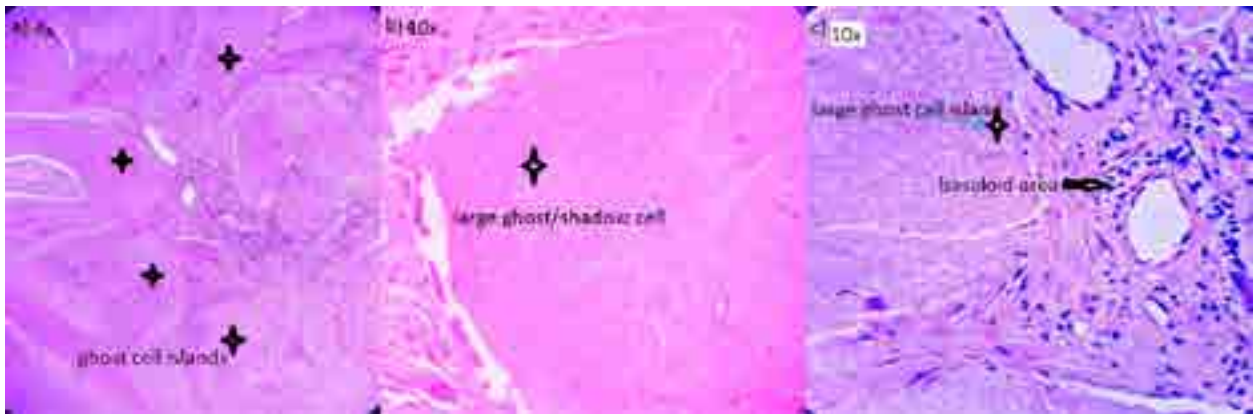

Fig. 4. Histopathology report – fig 4a highlights the islands of ghost cells at 4× magnification, fig 4b shows an enlarged ghost cell at 40× magnification and fig 4c image represents the basaloid cell area along with large ghost cell island at 10× magnification (H&E stain)

the cheeks followed by periorbital and preauricular regions.^{4,8,11} About 90–98% lesions reported in literature are found to be solitary lesions similar to our case with isolated lesion in right parotid region whereas 2–10% have been reported as multiple tumor lesions in the same individuals.^{4,9,11}

The various causative factors include history of trauma, insect bites, surgery, vaccination.^{9,12} Mutations in APC gene (adenomatous polyposis coli), CT NNB1 gene (catenin beta -1) are also been reported. An over expression of bcl-2 proto-oncogene has also been documented in literature to be associated with such tumors.¹³ Pilomatrixomas are also seen associated with various genetic disorders like turner's syndrome, Rubinstein-Taybi syndrome, myotonic dystrophy, trisomy 9, Gardner syndrome, celiac disease, 21-hydroxylase deficiency, Soto syndrome, trisomy 18, myosin heavy chains (MYH)-associated polyposis, and xeroderma pigmentosum. Also associated are some chronic diseases like sarcoidosis, hypercalcemia, increased levels of parathyroid hormones related protein and angiomyxoma.¹⁰ This case neither had any syndromic manifestation, nor had any history of earlier described causative factors. Hence, genetic mutation or over-expression could be a possible cause of the lesion here.

Clinically the lesion is slow growing tumoral mass, firm in consistency, non-tender and mobile. The presence of calcification gives firm characteristic to the lesion this is known as tent sign.¹⁴ Seesaw shaped skin “teeter-totter” sign, increases the chance of a right diagnosis.¹¹

As the clinical diagnosis is a dilemma, the other differential diagnosis should be kept in mind which include sebaceous cyst, dermoid cyst, epidermoid cysts, adenopathies, brachial remnants, degenerative fibroxanthomas, neurofibroma, basal cell carcinoma, preauricular sinuses and sialadenitis of the parotid gland.^{4,11} As in this case, a short duration with overlying non pinchable skin raised a possibility of malignancy. But at the same

time, a non-tender, mobile lesion with no history of facial weakness and pain pointed to a possibility of benign lesion.

As per literature review, the accuracy of clinical diagnosis for pilomatrixomas varies between 28.9% and 46%.¹ In a review conducted by et al., preoperative diagnosis was consistent with the pathological diagnosis of pilomatrixoma in only 100 cases (28.9%) out of 346 cases.⁸ In Kumaran et al. study, the diagnosis was achieved preoperatively in 46% of patients. Other diagnoses included sebaceous and dermoid cysts, foreign body reaction, calcification in lymph gland, and fat necrosis. Factors contributing to misdiagnosis include cystic lesions with varying consistency, punctum-like appearance, atypical location, and absence of clinically recognizable calcification.¹⁸

Imaging modalities are useful tools in differentiating pilomatrixomas by identifying calcifications, excluding parotid tumors in case of preauricular lesions, ruling out vascular or lymphatic tumors.¹⁵

However, the key role in diagnosing this tumor is held by histopathology examination. Typical features seen on histopath examination include enucleated ghost cells in the center and lobulated pattern with basaloid cells at the periphery.⁴ Cytology in our case was not confirmatory and revealed features with possibility of malignant lesion. As per literature as well, on FNAC the basaloid cells can be mistaken for intermediate cells of mucoepidermoid carcinoma, illustrating the risk of misdiagnosing pilomatrixoma for malignant tumor of parotid gland.¹⁹ So, these tumors can be misdiagnosed both clinically as well as pathologically.

Rarely complications are seen in PM cases, occasionally they grow to giant size i.e. > 5cm in diameter that cause compression symptom like facial nerve palsy.^{10,13,16} Malignant transformation is seen very rarely with PMs especially, in older patients and in patients with repeated tumor excision.^{9,16,17}

Recurrence rate ranges between 0% and 3% and most likely, this is due to inadequate surgical excision, and rarely is due to malignancy.^{4,8,9} Our patient is in follow-up for past 8 months with no symptoms or signs of recurrence or complication.

An exhaustive search of literature/PubMed was done using MeSH terms as pilomatricoma, parotid/preauricular region. A total of 113 cases were recorded in preauricular/parotid region which included 69 males and 44 females with a male to female ratio of 1.56:1. The mean age was found to be 30.6 years. All cases presented with swelling as the main chief complaint. All the cases were confirmed based on postoperative histopathological report. The size of tumor varied from as small as 0.2 cm to even more than 5 cm. All the lesions were managed by surgical excision. A maximum follow-up of 3.5 years was done and recurrence was reported in only 3 case post-surgical excision (1 case had recurrence after an interval of 3 months). These cases were managed with second surgical excision.

Conclusion

Pilomatricomas can be misdiagnosed in case of lesions in subcutaneous plane in parotid region. In such cases, the differential diagnosis should include tumor and non-tumor lesions of skin and parotid gland. Importance of frozen section should also be kept in mind and the pathologist should be engaged at the time of surgical excision of the tumor. Interposition of soft tissue between parotid and thin skin flap helps prevent gustatory sweating in such cases. A high index of suspicion is needed for proper diagnosis and management of these lesions.

Compliance with ethical standards

The study has not received funding from any organization or institution and does not involve any potential conflict of interest (financial and non-financial). Procedure performed in the study was in accordance with the ethical standards of the institution and with the 1964 Helsinki declaration and its later amendments.

Informed consent

Informed consent was obtained from patient in the study.

References

- Ciucă EM, Sălan AI, Camen A, Matei M, Șarlă CG, Mărgăritescu C. A patient with pilomatricoma in the parotid region: case report and review of the literature. *Rom J Morphol Embryol*. 2018; 59(3):917–926.
- Whittemore KR, Cohen M. Imaging and review of a large pre-auricular pilomatricoma in a child. *World J Radiol*. 2012; 4:228–230.
- Nadershah M, Alshadwi A, Salama A. Recurrent giant pilomatricoma of the face: a case report and review of the literature. *Case Rep Dent*. 2012; 2012:197273.
- Lan MY, Lan MC, Ho CY, Li WY, Lin CZ. Pilomatricoma of the head and neck: a retrospective review of 179 cases. *Arch Otolaryngol Head Neck Surg*. 2003; 129(12):1327–1330.
- Yamauchi M, Yotsuyanagi T, Saito T, Ikeda K, Urushidate S, Higuma Y. Three cases of giant pilomatricoma – considerations for diagnosis and treatment of giant skin tumours with abundant inner calcification present on the upper body. *J Plast Reconstr Aesthet Surg*. 2010; 63(6): e519–e524.
- Hashimoto K, Nelson RG, Lever WF. Calcifying epithelioma of Malherbe. Histochemical and electron microscopic studies. *J Invest Dermatol*. 1966; 46(4):391–408.
- Kaveri H, Punnya A. Pilomatricoma: a dermal analog of calcifying odontogenic cyst. *Indian J Dent Res*. 2008; 19(3):261–263.
- Pirouzmanesh A, Reinisch JE, Gonzalez-Gomez I, Smith EM, Meara JG. Pilomatricoma: a review of 346 cases. *Plast Reconstr Surg*. 2003; 112(7):1784–1789.
- Guinot-Moya R, Valmaseda-Castellon E, Berini-Ayres L, Gay-Escoda C. Pilomatricoma. Review of 205 cases. *Med Oral Patol Oral Cir Bucal*. 2011; 16(4): e552–e555.
- Yencha MW. Head and neck pilomatricoma in the pediatric age group: a retrospective study and literature review. *Int J Pediatr Otorhinolaryngol*. 2001; 57(2):123–128.
- Schwarz Y, Pitaro J, Waissbluth S, Daniel SJ. Review of pediatric head and neck pilomatricoma. *Int J Pediatr Otorhinolaryngol*. 2016; 85:148–153.
- Jeon H, Jeong SH, Dhong ES, Han SK. Pilomatricoma arising at an influenza vaccination site. *Arch Plast Surg*. 2014; 41(6): 775–777.
- Lazar AJ, Calonje E, Grayson W, Dei Tos AP, Mihm MC Jr, Redston M, McKee PH. Pilomatricomas contain mutations in CTNBN1, the gene encoding beta-catenin. *J Cutan Pathol*. 2005; 32(2):148–157.
- Sinhasan SP, Jadhav CR, Bhat RV, Amaranathan A. Pilomatricoma - presented as hypopigmented tender nodule: diagnosed by FNAC: a case report with review of literature. *Indian J Dermatol*. 2003; 58:405.
- Whittemore KR, Cohen M. Imaging and review of a large pre-auricular pilomatricoma in a child. *World J Radiol*. 2012; 4(5):228–230.
- Munding GS, Steinbacher DM, Bishop JA, Tufaro AP. Giant pilomatricoma involving the parotid: case report and literature review. *J Craniomaxillofac Surg*. 2011; 39(7):519–524.
- Honda A, Funakoshi T, Takahashi M, Kameyama K, Tanese K. A case of rapidly grown giant pilomatricoma: histological evaluation and immunohistochemical analysis of c-KIT. *Dermatol Sinica*. 2017; 35(2):104–105.
- Kumaran N, Azmy A, Carachi R, Raine PA, Macfarlane JH, Howatson AG. Pilomatricoma: accuracy of clinical diagnosis. *J Pediatr Surg*. 2006; 41(10):1755–8.
- Lemos LB, Brauchle RW. Pilomatricoma: a diagnostic pitfall in fine-needle aspiration biopsies. A review from a small county hospital. *Annals of Diagnostic Pathology*. 2004; 8(3):130–136