









Overuse of ionizing radiation imaging by skull X-ray scans for minor pediatric head trauma

Gharaibeh Ahmad ¹, Mahmoud M. Gharaibeh ², Ahmed Alwadiya ³,
Antonia Lackova ⁴, Robert Cellar ¹, Istvan Mitro ¹, Vladimir Filip ¹, Marek Lacko ¹

¹ Teaching Department of Orthopedics and Musculoskeletal Trauma, Pavol Jozef Šafárik University, Kosice, Slovakia

² Teaching Department of Dentistry, Princes Basma Teaching Hospital, Irbid, Jordan

³ Royal Derby Hospital, Derby, United Kingdom

⁴ Neurology Department, Pavol Jozef Šafárik University, Kosice, Slovakia

ABSTRACT

Introduction and aim. The assessment of light head trauma in pediatric patients (GCS 14-15) often involves the use of skull X-rays for forensic reasons. This study aims to evaluate the necessity of radiographic imaging and reducing the overuse of X-rays, and developing Slovak guidelines for the appropriate use of X-rays and computed tomography (CT) in pediatric head trauma cases.

Material and methods. This retrospective descriptive study analyzed records from children with head trauma seen at trauma clinics over a period of one year. The study focused on the number of radiographic images (CT and X-rays) performed on pediatric patients and assessed the appropriateness of these imaging techniques.

Results. Out of 1168 pediatric patients with head trauma, 831 (71%) had simple head injuries, 295 (25.26%) had wounds in the head area, 17 (1.45%) had fractures, 23 (1.97%) had concussions, and 2 (0.17%) had intracranial hematomas. A total of 1097 (93.9%) children with head trauma underwent imaging: 1032 had X-rays and 65 had CT scans. The study found that only 3.42% of patients actually needed radiation.

Conclusion. The majority of pediatric head trauma cases were minor and not associated with brain injury, highlighting the overuse of radiographic imaging in these cases.

Keywords. epidemiology, guidelines, ionization, overuse, pediatric head trauma, radiological imaging

Introduction


Head injuries are a common reason for emergency room visits, especially among children.^{1,2} These injuries can range from minor to severe and can be classified as closed or open (penetrating) head injuries. Closed head injuries involve a blow to the head without breaking the skull, while penetrating injuries occur when an object breaks the skull and enters the brain, often resulting from high-speed accidents or gunshot wounds.^{1,2}

Severe head trauma is less common in younger children due to their smaller body size and lower fall speeds, which can typically be absorbed by their well-padded skin and elastic skeleton. However, assessing head trauma in children remains challenging, particularly in distinguishing between minor and clinically significant injuries.^{1,3-5} In Slovakia, the Pediatric Glasgow Coma Scale (PGCS) is used to evaluate head trauma in children. For light head trauma (GCS 14-

Corresponding author: Gharaibeh Ahmad, e-mail: gharaibeh@seznam.cz

Received: 17.08.2024 / Revised: 25.09.2024 / Accepted: 6.10.2024 / Published: 30.03.2025

Ahmad G, Gharaibeh MM, Alwadiya A, Lackova A, Cellar R, Mitro I et al. Overuse of ionizing radiation imaging by skull X-ray scans for minor pediatric head trauma. *Eur J Clin Exp Med*. 2025;23(1):141–145. doi: 10.15584/ejcem.2025.1.21.



15), a skull X-ray in two views and, in some cases, a head CT scan are performed for forensic reasons (parents might complain to the Slovak health care surveillance authority for an insufficient examination of their child).⁶ Simple or light head trauma in pediatric age (PGCS 14-15) means eye opening spontaneously, localized pain or without pain, crying, obeying commands, oriented and conversing, and using appropriate words. Further investigations are sometimes performed to alleviate family fears or due to family exaggeration of the trauma history. However, there is no standardized guideline similar to the Pediatric Emergency Care Applied Research Network (PECARN) guidelines to assist physicians in determining when to use CT scans.^{7,8} The most common symptoms for severe head trauma are paleness, somnolence, and vomiting, caused by car accidents, including pedestrians, bicycle injuries, or falling from a height.⁵

The Appropriateness Criteria provide evidence-based guidelines for the use of CT scans in children with head trauma aims to minimize the risks associated with ionizing radiation.^{8,9} While MRI or magnetic resonance spectroscopy (MRS) is an effective alternative, its use in children is limited due to the need for sedation or general anaesthesia.¹⁰⁻¹²

Skull X-rays of minor traumatic brain injury does not bring any benefit for diagnosis.¹³ For the group aged 0-2 years, a skull X-ray is indicated only if a skull fracture is suspected and the CT scan is not indicated immediately for minor head injury.^{14,15} Portable point-of-care ultrasound has high diagnostic precision and valid in children with skull fracture and closed blunt head trauma.^{15,16} Also we can reduce the radiation of CT scans by monitoring the child with blunt head trauma and minor skull injury.¹⁶⁻¹⁸

Aim

The primary aim of this study is to reduce the overuse of X-rays in pediatric head trauma cases. By evaluating the incidence of head trauma and the use of radiographic imaging, the study seeks to create a database for further research and develop Slovak guidelines similar to PECARN to ensure effective and appropriate imaging practices.

Material and methods

The study was conducted based on a review of medical records of 3261 pediatric patients aged 1 to 17 years with trauma who were in trauma clinics in the emergency teaching department and the radiology department. Institutional forms were archived and evaluated in the year 2018. The trauma clinic of the University Hospital, with 1356 beds, is the second-largest hospital in Slovakia, providing a high-standard of healthcare to patients from the Kosice area and Eastern Slovakia. One-thou-

sand one-hundred and sixty-eight patients had head trauma, which constituted 35.82% of all patients treated during that period. Information was used regarding age, types of injuries, the number head trauma images taken, and the severity of head trauma.

The assessments were based on radiological examination: reviews of X-rays of the skull and head, and CT, depending on indications.

Data analysis

Data were analyzed using Microsoft Excel, employing statistical features such as the Chi-square test, standard deviation (SD), and percentage comparison (Microsoft, Redmond, Washington, USA). The hospital's ethics committee reviewed and approved the study (Ethical Committee of the Louse Pasteur University Hospital, 2019/UK/6034).

Sample selection

The sample included all pediatric patients with head trauma seen at the trauma clinics during the study period. Patients were selected based on the criteria of head trauma and the need for radiographic imaging as recorded in their medical files.

Results

A total of 3261 pediatric patients (0-17 years) with trauma were evaluated in the trauma clinics, with a SD of 654.07. Among these, 1168 patients had head trauma (35.82%): 831 had simple head injuries, 295 had wounds in the head area, 17 had fractures: 10 in skull area, 4 in the fascial area and 3 nasal bone fractures, 23 had concussions, and 2 had intracranial hematomas (SD=355.51) (Fig. 1, Table 1).

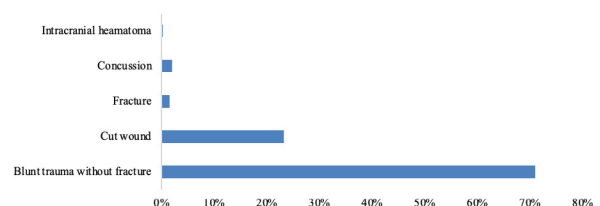


Fig. 1. Head trauma incidence due to severity

Table 1. Types of head trauma

	Blunt trauma	C/W	Fracture	Concussion	Intracranial hematoma
Skull trauma	753	210	10	23	2
Around eye trauma	30	44	0		
Ear trauma	2	3	0		
Max fax area	7	27	4		
Nose	39	11	3		
Total	831	295	17	23	2

Most children (1097 patients, 93.9%) with blunt head trauma underwent radiological imaging (X-ray or CT scan) following the hospital's guidelines. In the age group under 4 years, 738 had light head trauma (89%), and only 93 patients had head contusions in the 4–17 years age group. Cut wounds were observed in 187 patients under 4 years (63%), and 108 patients above 3 years. Seventeen patients had fractures: 14 were less than 4 years old (82%). Twenty-three patients had concussions: 8 were less than 4 years old (35%) and 15 were older than three years (65%). Two patients had intracranial hematomas (See table No. 2), both above three years old (Fig. 2, Table 2). All 42 patients with fractures, concussions, and hematomas were admitted to the hospital, along with 4 patients with blunt head trauma and cut wounds (C/W).

Table 2. Types of head trauma due to age group*

Age group	Light contusion	C/W	Fracture	Concussion	Intracranial hematoma
0–3 years old	738	187	14	8	0
4–17 years old	93	108	3	15	2

* C/W – cut wound

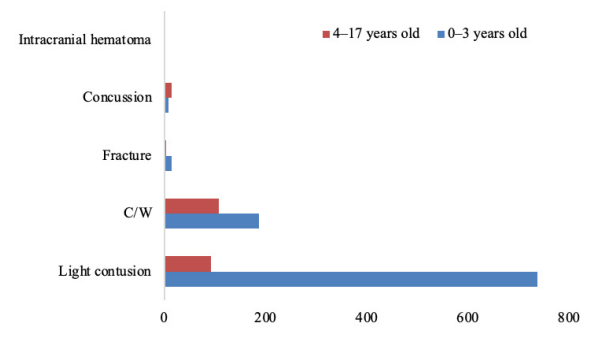


Fig. 2. Head trauma incidence due to age

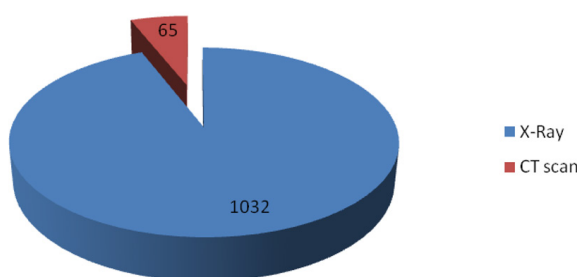


Fig. 3. Number of imaging of head trauma due to type

Among the 1168 patients, 1097 underwent radiation (X-ray or CT), representing 93.90% (see figure 3). One-thousand one-hundred and thirty-two underwent X-ray imaging (anteroposterior and lateral views) with an average ionizing radiation of 5 mGray per patient, and 65 underwent CT scans with an average ionizing ra-

diation of 20.865 mGray per patient (the hospital's X-ray machine is old with hard copies only). Only 3.42% of patients actually needed radiation.

We used the “N-1” Chi-square test to compare the percentage of patients who were irradiated with the percentage of patients who needed radiation (PGCS≤13). The test result showed that the number of irradiated patients was significantly different from the number of patients needing irradiation. $\chi^2(1) = 1913.777, p < 0.001$. The percent difference is 90.50% with a confidence interval of 88.56–92.02% (Table 3).

The p-value is much below 0.05 (or 0.001), showing that the disparity between the observed and expected frequencies is statistically significant. This indicates that the real amount of irradiated patients deviates significantly from what would be anticipated based on adherence to the PGCS criteria for radiation use.

Table 3. Table of Chi-Square test applied

Category	Observed frequency	Expected frequency	Chi square statistic	Degrees of freedom	p
Irradiated	1097	1057	15.92813248	1	<0.001
Not Irradiated	71	111			
Total	1168	1168			
Calculations					
Expected frequency (needing radiation)	90.5% * total patients				
Total patients	1168				
Calculation	$(90.5/100) * 1168$				
Expected frequency (needing radiation)	1057.24				
Expected frequency (Not needing radiation)	Total patients – expected frequency (needing radiation)				
Calculation	$1168 - 1057.24$				
Expected frequency (Not needing radiation)	110.76				
Degree of freedom	$df = (r-1) \times (c-1)$				
	$(2-1) \times (2-1) = 1 \times 1 = 1$				

Discussion

This study analyzed 1168 pediatric patients with head trauma in the emergency department. Most (71%) did not require medical care or assessment, having no neurological deficit (PGCS 15) with minor trauma, but were seen due to parental concern.¹ This is the first study in Slovakia to address the use of ionizing radiation in the assessment of pediatric head injury, which is a major strength.¹

The clinical challenge in evaluating minor head trauma in pediatric patients (PGCS 15) is identifying those with clinically important traumatic brain injury while limiting imaging and radiation exposure. Neuroimaging, usually with CT or USG is highly sensitive for identifying brain injuries requiring acute intervention.^{7,8,10,16,17} A study in Switzerland emphasized cost-effective and quick imaging.¹¹ Monitoring and raising awareness is the gold standard, which aligns with our findings about overuse of

skull X-rays.¹¹ A study which was conducted in the Czech Republic showed that in 93.2% cases, the skull X-ray was negative, which is similar to our study (96.58%). Skull X-rays of minor traumatic brain injury does not bring any benefit for diagnosis aligns with our findings and for an Iranian age group between 0-2 years. skull X-Ray was indicated only if a skull fracture was suspected. Furthermore the CT scan was not indicated immediately for minor head injury.^{13,15}

An advanced portable point-of-care ultrasound had high diagnostic precision and was valid in children with skull fractures and closed blunt head trauma.^{16,17} Also, we can reduce the radiation of CT scans by monitoring the child in the emergency room (ER) or in the department with blunt head trauma and minor skull injuries.^{18,19}

Most infants and children with minor head trauma can be safely discharged home after careful clinical evaluation without undergoing imaging. However, the current lack of clear guidelines in Slovakia leads to the overuse of ionizing radiation. We propose new guidelines to limit X-ray and CT use to patients with significant injury risk. MRI and MRS, while effective, require sedation or anesthesia in young children (0-14 years).^{7,8,12} On the other hand Nour et al. recommend skull X-ray scans only if a skull fracture is suspected for younger children than 2 years.¹⁴

A study which was done in Poland (1993-2002), showed that they had about 12 facial fracture annually (115 in 10 years).²⁰ Evaluation of pediatric head trauma by neuroimaging is an integral part.²¹ But skull radiography can be removed from imaging guidelines.²¹ It is recommended if a skull fracture is suspected for younger children than 2 years.²²

Study limitations

This study had limitations, including the data from a single hospital. Also, realization of the ultrasonography of the pediatric brain is very difficult in our hospital.

Conclusion

Head trauma is common in childhood, with most cases being minor and not associated with brain injury. However, some low-risk children may have significant injuries. The Ministry of Health and Medical Chamber should review and create new guidelines like ACR and PECARN to limit unnecessary radiation exposure (X-rays) and support other valid methods like USG. A health awareness project on radiation risks and initial signs for seeking medical assistance in the ER is recommended.

Acknowledgment

We thank the staff of the Emergency and Radiology departments and our colleagues for their assistance in this study.

Declarations

Funding

The work was supported by the Scientific Grant Agency of the Ministry of Education, Science, Research, and Sports of the Slovak Republic – VEGA no.1/0598/20.

Author contributions

Conceptualization, G.A. and M.M.G.; Methodology, G.A.; Software, G.A. and A.L.; Validation, R.C., I.M. and V.F.; Formal Analysis, G.A.; Investigation, G.A.; Resources, M.M.G.; Data Curation, G.A.; Writing – Original Draft Preparation, G.A.; Writing – Review & Editing, G.A.; Visualization, G.A.; Supervision, G.A.; Project Administration, A.A.; Funding Acquisition, M.L.

Conflicts of interest

All authors declared that the research was conducted in the absence of any commercial or financial relationships that could be construed as a potential conflict of interest. All authors have no competing conflicts of interest.

Data availability

The data that support the findings of this study are available from the corresponding author upon reasonable request.

Ethics approval

The study was reviewed, considered, and approved by the Ethical Committee of Louis Pasteur University Hospital (2019/UK/6034).

References

- Gharaibeh A. Over use of ionization radiation imaging with paediatric head trauma 2020. <https://www.researchsquare.com/article/rs-132823/v1>. Accessed February 4, 2022.
- Alexiou GA, Sfakianos G, Prodromou N. Pediatric head trauma. *J Emerg Trauma Shock*. 2011;4(3):403-408. doi:10.4103/0974-2700.83872
- Kent, George C, Carr, Robert K. Comparative Anatomy of the Vertebrates, New York, NY: McGraw-Hill. 9; 2002.
- Wan D, Small KH, Barton FE. Face Lift. *Plastic and Reconstructive Surgery*. 2015;136(5):676-689. doi: 10.1097/PRS.0000000000001695
- Mihic J, Rotim K, Marcikić M, Smiljanić D. Head injury in children. *Acta Clin Croat*. 2011;50(4):539-548.
- Glasgow coma scale. Web site. <https://www.rainbowrehab.com/understanding-paediatric-glasgow-coma-scale/>. Accessed February 4, 2020.
- Indikácie CT vyšetrení, Web site. https://www.researchgate.net/publication/292983969_INDİKACIE_CT_VYŠETRENIA_PRI_MIERNYCH_URAZOCH_MOZGU_CT_indication_in_mild_brain_injury. Accessed February 4, 2022.
- <https://www.uptodate.com/contents/image?imageKey=E-M%2F58477>. Accessed 2022 February 4, 2020.

9. Babl FE, Pfeiffer H, Dalziel SR, et al. Paediatric intentional head injuries in the emergency department: A multicentre prospective cohort study. *Emerg Med Australas.* 2019;31(4):546-554. doi: 10.1111/1742-6723.13202
10. Ryan ME, Palasis S, Saigal G, et al. ACR Appropriateness Criteria head trauma-child. *J Am Coll Radiol.* 2014;11(10):939-947. doi: 10.1016/j.jacr.2014.07.017
11. Exadaktylos AK, de Moya MA, Lecky F, et al. Imaging and resuscitation in trauma. *Emerg Med Int.* 2011;2011:313404. doi: 10.1155/2011/313404
12. Guz W, Bober Z, Ożóg Ł, et al. Clinical application of advanced neuroimaging techniques- Magnetic Resonance Spectroscopy. *Eur J Clin Exp Med.* 2017;15(2):133-140. doi: 10.15584/ejcem.2017.2.6
13. Nekuda V, Krtička M, Miklošová B, Švancara J, Chovanec M. Importance of Skull X-ray in Head Trauma. *Acta Chir Orthop Traumatol Cech.* 2019;86(5):342-347.
14. Nour A, Goldman RD. Skull x-ray scans after minor head injury in children younger than 2 years of age. *Can Fam Physician.* 2022;68(3):191-193. doi: 10.46747/cfp.6803191
15. Dehbozorgi A, Mousavi-Roknabadi RS, Hosseini-Marvast SR, et al. Diagnosing skull fracture in children with closed head injury using point-of-care ultrasound vs. computed tomography scan. *Eur J Pediatr.* 2021;180(2):477-484. doi: 10.1007/s00431-020-03851-w
16. Alexandridis G, Verschuuren EW, Rosendaal AV, Kanhai DA. Evidence base for point-of-care ultrasound (POCUS) for diagnosis of skull fractures in children: a systematic review and meta-analysis. *Emerg Med J.* 2022;39(1):30-36. doi: 10.1136/emmermed-2020-209887
17. Doğan K, Doğan A, Karaküçük SN, Hakkoymaz H, Güngör Ş. Evaluation of Radiation Exposure in Paediatric Cranial Trauma Patients. *KSU Medical Journal.* 2023;18(3):1-6. doi: 10.17517/ksutfd.1206132
18. Bako D, Özer U, Beydoğan E. Computed Tomography Overuse in Pediatric Minor Head Trauma: Insights from a Single-Center Experience. *Klin Padiatr.* 2024;236(1):11-15. doi: 10.1055/a-2156-9780
19. Mehmood A, Agrawal P, Allen KA, Al-Kashmiri A, Al-Busaidi A, Hyder AA. Childhood injuries in Oman: retrospective review of a multicentre trauma registry data. *BMJ Paediatr Open.* 2018;2(2). doi: 10.1136/bmj-po-2018-000310
20. Lewandowski B, Kulig T. Epidemiological and clinical evaluation of facial fractures in children. *Eur J Clin Exp Med.* 2006;4:259-264. doi: 10.15584/ejcem.2017.2.6
21. Canty KW, Keogh A, Rispoli J. Neuroimaging considerations in abusive head trauma. *Semin Pediatr Neurol.* 2024;50:101140. doi: 10.1016/j.spn.2024.10114020
22. Cosgrave L, Bowie S, Walker C, Bird H, Bastin S. Abusive head trauma in children: radiographs of the skull do not provide additional information in the diagnosis of skull fracture when multiplanar computed tomography with three-dimensional reconstructions is available. *Pediatr Radiol.* 2022;52(5):924-931. doi: 10.1007/s00247-021-05256-9