




CASUISTIC PAPER

Neonatal lupus in an infant with maternal history of Jessner's lymphocytic infiltrate

Bhumesh Kumar Katakam ¹, Arunima Dhabal ²,
Narsimha Rao Netha Gurram ¹, Sudharani Chintagunta ¹

¹ Department of Dermatology, Venereology and Leprosy, Gandhi Medical College and Hospital, Secunderabad, India

² Department of Dermatology, Venereology and Leprosy, Jagannath Gupta Institute of Medical Sciences and Hospital, Kolkata, India

ABSTRACT

Introduction and aim. Neonatal lupus erythematosus (NLE) is a rare autoimmune condition occurring in infants born to mothers with circulating antinuclear autoantibodies, particularly anti-Ro and anti-La. It presents with a characteristic cutaneous rash, which may be accompanied by systemic manifestations. The condition is mostly self-limited, although congenital heart block, if present, is irreversible. We report a rare case of cutaneous NLE in an infant of a mother with a prior history of Jessner's lymphocytic infiltration of skin (JLIS), which is arguably a variant of cutaneous lupus erythematosus (LE).

Description of the case. This report concerns an infant presenting with cutaneous manifestations of NLE, without any systemic involvement. The mother was asymptomatic, but had been previously diagnosed with JLIS. The diagnosis of NLE was made based on serological results from both the infantile and maternal blood. Conservative management was sufficient to achieve complete resolution.

Conclusion. The case underscores the importance of considering NLE in infants presenting with annular rash, even in asymptomatic mothers with no known rheumatic disease. It also suggests that JLIS may belong to the same spectrum as LE, rather than being a separate entity. This warrants careful prenatal monitoring in mothers with a concurrent or prior diagnosis of JLIS.

Keywords. cutaneous lupus erythematosus, Jessner's lymphocytic infiltrate, neonatal lupus

Introduction

Neonatal lupus erythematosus (NLE) is a spectrum of cutaneous and systemic manifestations occurring in infants due to transplacental transfer of maternal antinuclear autoantibodies. The most common manifestations include cutaneous rash, hepatitis, cytopenias and congenital heart block. While most of these are transient and resolve within a few months with clearance of maternal antibodies, congenital heart block (CHB) is irreversible and requires urgent intervention.¹⁻⁴ The mothers of affected infants often have an autoimmune

connective tissue disorder, although they may remain asymptomatic and undiagnosed at the time of delivery.⁵

Jessner's lymphocytic infiltration of the skin (JLIS) is an entity that has been debatably considered as a dermal variant of lupus erythematosus (LE).⁶ It is a benign disease characterized by asymptomatic erythematous papules, or annular plaques, usually located on the face or back, with histological evidence of perivascular or periadnexal lymphocyte infiltration under a normal epidermis.⁷

NLE is a rare condition with only a few reported cases in current literature. Furthermore, a case of NLE,

Corresponding author: Bhumesh Kumar Katakam, e-mail: drbhumesh124@gmail.com

Received: 30.01.2024 / Revised: 22.03.2024 / Accepted: 11.04.2024 / Published: 30.12.2024

Katakam BK, Dhabal A, Gurram NRN, Chintagunta S. Neonatal lupus in an infant with maternal history of Jessner's lymphocytic infiltrate. *Eur J Clin Exp Med*. 2024;22(4):961–964. doi: 10.15584/ejcem.2024.4.1.



where the mother had a prior diagnosis of JLIS, has not been previously reported and ours is the first such case.

Aim

We present the case of a two-month old male infant with cutaneous NLE, born to a mother with no known history of collagen vascular disease, but previously diagnosed with JLIS.

Description of the case

A two-month-old male baby presented with reddish-brown patches on the face and body. The lesions first appeared about one week after birth, as a red rash around both the eyes. This was followed after two weeks by multiple raised patches on the face and body, which seemed to aggravate on sun exposure. On consultation with a primary physician, desonide cream was applied for a week, after which the redness decreased. There was no history of any fever, irritability or systemic complaints. The baby was born by Caesarean delivery (elective) without any complications during the antenatal and perinatal period. The parents were non-consanguineous and did not have any previous issue. The mother complained of having developed a reddish elevated skin lesion on the right cheek with aggravation on sun exposure, four years back. A skin biopsy from the lesion was suggestive of Jessner's lymphocytic infiltrate. The lesion had resolved after two months of treatment with topical steroids, with no subsequent recurrence. She had no history of recurrent fever, arthralgia, photosensitivity or any other cutaneous or systemic complaints.

Examination of the infant revealed multiple erythematous to hyperpigmented macules and annular plaques distributed bilaterally on the face, trunk and extremities (Fig. 1). The facial lesions involved the forehead and periorbital areas. Mucosal involvement was absent and no abnormality was detected on systemic evaluation.

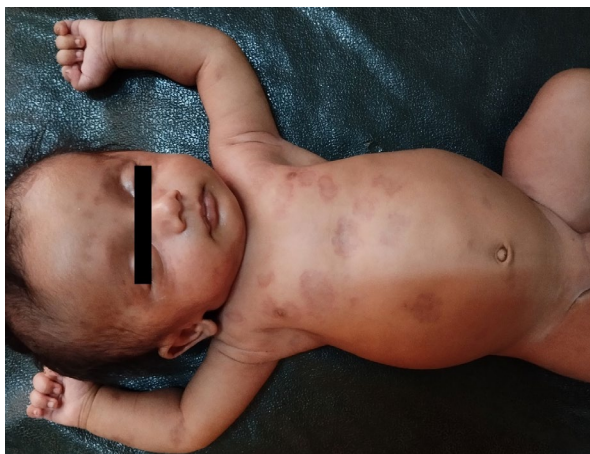

Fig. 1. Erythematous macules and annular plaques distributed on the face, trunk and extremities

Laboratory investigations of the baby demonstrated negative results on potassium hydroxide (KOH) mount for fungal elements and qualitative serum Venereal Disease Research Laboratory (VDRL) test, but a strongly positive antinuclear antibody (ANA) titer of 1:1000 speckled pattern, along with positive anti-Ro and anti-La antibodies. Blood counts revealed anemia (hemoglobin 8.5 g/dL, erythrocyte count 2.9 million cells/cmm) and normal leucocyte and platelet counts. Peripheral smear revealed normocytic normochromic anemia. Liver enzyme levels were within normal limit. An electrocardiogram and a two-dimensional echocardiogram did not reveal any cardiac abnormality. Maternal serum was found to be positive for ANA (131.8 IU/mL; reference range <20 IU/mL), as well as, anti-Ro and anti-La. Thus, a diagnosis of cutaneous NLE was made based on the characteristic skin lesions and laboratory findings. Photo-protection was advised along with iron, vitamin C and D₃ supplementation. The lesions showed gradual resolution on subsequent monthly follow-up and the hemoglobin level normalized by three months. The ANA titer repeated every four months showed a gradual fall and was negative at 14 months of age. Anti-Ro and anti-La, repeated at 18 months, were found to be negative. The mother remained clinically asymptomatic throughout follow-up.

Discussion

NLE is a rare condition with an incidence of 1 in 20,000 live births, preferentially affecting females.^{2,3} The maternal autoantibodies implicated in 98% cases are anti-Ro/SS-A and anti-La/SS-B, in addition to anti-U1-ribonucleoprotein (anti-U1-RNP).⁴ These antibodies bind to their corresponding antigens in neonatal tissue causing inflammation, which may sometimes progress to fibrosis and scarring, especially in the cardiac conduction system.^{1,4} Mothers often have known rheumatic diseases such as systemic lupus erythematosus (SLE), Sjogren syndrome, rheumatoid arthritis, mixed connective tissue disease (MCTD) or undifferentiated autoimmune conditions.¹⁻³ In up to 40-60% cases, seropositive mothers may also be asymptomatic.¹ Our patient is the first reported case of NLE, where the mother had a prior diagnosis of JLIS.

JLIS is a benign condition, first described by Max Jessner and Norman Kanof, characterized clinically by firm erythematous papules or annular plaques on photo-exposed areas, especially the face.⁸ The nomenclature is based on the histological feature of a dense dermal perivascular or periadnexal lymphocytic infiltrate. This entity has arguably been linked to LE by several authors, including Jessner himself.⁶⁻⁸ A comparative study between 32 patients with JLIS and 14 with tumid LE showed remarkable similarities between the two in terms of clinical and histopathological characteristics.⁷

Clinically, common features shared by the two entities included predilection for middle-aged females, facial lesions, photosensitivity, lesional morphology, lack of systemic involvement and good response to antimalarials. Histologically, both conditions showed absent or minimal epidermal changes and dermal lymphocytic infiltrate. The only significant pathological differences were the relatively lower frequency of epidermal atrophy and a comparatively denser sleeve-like perivascular lymphocytic infiltrate in JLIS as compared to LE tumidus.⁷

Although several authors have described certain immunohistochemical features such as polyclonal CD8 infiltrate and plasmacytoid monocytes in JLIS as distinctive features differentiating it from LE, most of these studies were inadequately designed and excluded patients with features suggestive of LE from the study population giving rise to biased results.^{9,10} Similarly, a longitudinal study of 100 patients with JLIS reported no evolution to LE during follow-up arguing in favor of the two being separate entities, but this study had excluded two patients with typical JLIS since they were already diagnosed with discoid LE.⁹ On the contrary, Lipsker et al. in their analysis of 210 patients of JLIS, found 7.6% patients with typical features of LE, occurring either previously, concomitantly or later in life. This led them to propose the classification of JLIS as a dermal variant of LE.⁶ The occurrence of NLE in our patient in the context of maternal history of JLIS further substantiates this hypothesis.

The cutaneous manifestations noted in our case were representative of a typical presentation of NLE. In severe cases, cardiac conduction abnormalities may occur ranging from prolonged PR interval to complete heart block. The risk of CHB is lower in infants of mothers with SLE, as compared to those with Sjogren syndrome or undifferentiated autoimmune syndrome.¹ Other manifestations of NLE include cytopenias, hepatitis, neurological abnormalities (hydrocephalus, macrocephaly, aseptic meningitis) and pulmonary involvement (pneumonitis).^{1,2} Lipsker et al. mentioned that among patients with cutaneous LE, dermal variants, like tumid LE and possibly JLIS, have the best prognosis in terms of systemic involvement and cutaneous sequelae.⁶ In accordance with this, the absence of extracutaneous manifestations in our case further indicates a low risk of NLE complications in cases with maternal JLIS.

The diagnosis of NLE is based on characteristic clinical features and presence of specific antibodies in the infantile and maternal sera. It should be differentiated from seborrheic dermatitis, atopic dermatitis, tinea corporis, early congenital syphilis, annular erythemas, and Langerhans cell histiocytosis.^{1,3} Cutaneous lesions usually improve with photoprotection and topical steroids. In severe cases, systemic steroids or antimalarials may be necessary. A multidisciplinary approach is imperative for early detection and management of extra-cutaneous manifes-

tations, especially in case of CHB, where a pacemaker is invariably required. Affected infants are also more prone to develop autoimmune diseases in later life.³

Parents should be counselled regarding the two-to-three-fold higher risk of recurrence of NLE in subsequent pregnancies, particularly if the infant has CHB.¹ In such cases, prenatal monitoring by fetal echocardiography starting from the 16th gestational week is recommended.² Furthermore, our case underscores the importance of monitoring pregnant mothers with concurrent or previous history of JLIS. Frequent ANA titer estimation and, if required, anti-Ro, anti-La and fetal echocardiography should be carried out to rule out the development of NLE in such cases.

Our study was limited by resource constraints, as a result of which, we could not conduct serial titers of anti-Ro and anti-La antibodies, which are more specific for NLE, during follow-up. A skin biopsy from the lesions would also have added diagnostic value to our case. Additionally, the diagnosis of JLIS in the mother was based solely on the histopathologist's record as neither the clinical nor the histological images were available to us.

Conclusion

Our case highlights the importance of suspecting NLE in infants presenting with typical cutaneous lesions, even in the absence of maternal history of autoimmune connective tissue diseases. The development of NLE in the scenario of maternal history of Jessner's lymphocytic infiltrate emphasizes the possibility of JLIS belonging to the spectrum of LE, rather than a separate entity. Consequently, pregnant mothers who have had JLIS at any point in their lives, should be carefully followed up during pregnancy for signs of NLE developing in the fetus.

Declarations

Funding

No funding was received for this report.

Author contributions

Conceptualization, B.K.K., G.N.R.N. and S.C.; Methodology, A.D.; Software, B.K.K. and A.D.; Resources, B.K.K. and S.C.; Data Curation, B.K.K. and A.D.; Writing – Original Draft Preparation, A.D. and B.K.K.; Writing – Review & Editing, G.N.R.N. and S.C.

Conflicts of interest

The authors declare that there are no conflicts of interest regarding the publication of this article.

Data availability

The data used and/or analyzed during the current study are open from the corresponding author on reasonable request.

Ethics approval

Informed consent for inclusion was obtained from the legal guardian of the study participant, who was a minor.

References

1. Hon KL, Leung AK. Neonatal lupus erythematosus. *Auto-immune Dis.* 2012;2012:301274. doi: 10.1155/2012/301274
2. Derdulska JM, Rudnicka L, Szykut-Badaczewska A, et al. Neonatal lupus erythematosus - practical guidelines. *J Perinat Med.* 2021;49:529-538. doi: 10.1515/jpm-2020-0543
3. Sukumaran S, Singh D. Cutaneous Neonatal Lupus Erythematosus: A Case Report. *Cureus.* 2022;14:e22279. doi: 10.7759/cureus.22279
4. Kim D, Lee S, Kim T, et al. Two Cases of Neonatal Lupus and Literature Review. *Soonchunhyang Med Sci.* 2018;24:76-80. doi: 10.15746/sms.18.013
5. Savino F, Viola S, Tarasco V, Locatelli E, Ricagni A, Coppo P. Neonatal lupus erythematosus: a cutaneous cases based update. *Ital J Pediatr.* 2016;42:1-5. doi: 10.1186/s13052-015-0208-5
6. Lipsker D, Mitschler A, Grosshans E, Cribier B. Could Jessner's lymphocytic infiltrate of the skin be a dermal variant of lupus erythematosus? An analysis of 210 cases. *Dermatology.* 2006;213:15-22. doi: 10.1159/000092832
7. Rémy-Leroux V, Léonard F, Lambert D, et al. Comparison of histopathologic-clinical characteristics of Jessner's lymphocytic infiltration of the skin and lupus erythematosus tumidus: Multicenter study of 46 cases. *J Am Acad Dermatol.* 2008;58:217-223. doi: 10.1016/j.jaad.2007.09.039
8. Jessner M, Kanof B. Lymphocytic infiltration of the skin. *Arch Dermatol.* 1953;68:447-449.
9. Toonstra J, Wildschut A, Boer J, et al. Jessner's lymphocytic infiltration of the skin. A clinical study of 100 patients. *Arch Dermatol.* 1989;125:1525-1530.
10. Willemze R, Vermeer BJ, Meijer CJ. Immunohistochemical studies in lymphocytic infiltration of the skin (Jessner) and discoid lupus erythematosus. *J Am Acad Dermatol.* 1984;11:832-840. doi: 10.1016/s0190-9622(84)80460-0