




Morphometric analysis of dry acetabulum and iliac bones from anatomy museums in south eastern Nigeria with relation to clinical practice

Henry Chinedum Ekwedigwe ¹, Emmanuel Esom², Amechi Uchenna Katchy^{2,3},
Udo Ego Anyaehie¹, Ignatius Ikem Ozor⁴, Remigius Tochukwu Ekwunife¹,
Chikaodi Victoria Aniagu³

¹ Department of Orthopedics, National Orthopedic Hospital, Enugu, Institute of Orthopedics, Plastic and Reconstructive Surgery, Abia State University, Nigeria

² College of Medicine. University of Nigeria, Enugu, Nigeria

³ College of Medicine. Godfrey Okoye University Enugu, Enugu, Nigeria

⁴ College of Medicine, Enugu State University of Science and Technology, Enugu State University Teaching Hospital, Enugu, Nigeria

ABSTRACT

Introduction and aim. Good outcomes of total hip replacement and acetabular surgeries have been linked to proper understanding of the morphometry of acetabular and iliac bones. The aim of this study was to analyze the clinical morphometry of dry acetabulum and iliac bones in southeastern Nigeria.

Material and methods. The measurements were done on human hip bones in anatomy museums using a Vernier caliper. The acetabular and iliac bone parts were measured.

Results. A total of 148 dry hip bones were measured during the study. The mean acetabular depth and diameter are 32.10 ± 2.33 mm, and 53.93 ± 2.74 mm respectively. The mean thicknesses of the acetabular walls are 5.88 ± 1.38 mm, 12.64 ± 1.84 mm, 15.79 ± 2.07 mm and 19.74 ± 2.18 mm for the antero-inferior, antero-superior, postero-inferior and postero-superior walls respectively. The distances between landmarks on the iliac bone are: anterior-inferior-iliac-spine – posterior-inferior-iliac-spine = 112.91 ± 8.01 mm, posterior-superior-iliac-spine – anterior-inferior-iliac-spine = 135.29 ± 8.04 mm, anterior-inferior-iliac-spine – anterior-superior-iliac-spine = 34.98 ± 9.55 mm, posterior-superior-iliac-spine – upper-edge-of-acetabulum = 119.14 ± 7.83 mm and anterior-superior-iliac-spine – nearest-edge-of-acetabulum = 55.71 ± 5.60 mm. The regression model for prediction of diameter of the acetabulum using the depth of the acetabulum shows that for every 1 mm increase in the acetabular depth, the acetabular diameter increases by 0.312 times. The regression equation is “ $Y = bx + a$ ”; $Y =$ acetabular diameter, $x =$ acetabular depth, $b =$ margin of error = 0.312, and $a =$ constant determined to be 43.919.

Conclusion. The study established the mean values and the relationship between acetabular depth and diameter.

Keywords. acetabular depth, acetabular diameter, acetabular wall thickness, anterior superior iliac spine, posterior superior iliac spine

Corresponding author: Henry Chinedum Ekwedigwe, e-mail: ekwedyte@yahoo.com or Amechi Uchenna Katchy, e-mail: amechikatchy@gouni.edu.ng

Received: 30.03.2024 / Revised: 3.06.2024 / Accepted: 6.06.2024 / Published: 30.12.2024

Ekwedigwe HC, Esom E, Katchy AU, Anyaehie UE, Ozor II, Ekwunife RT, Aniagu CV. Morphometric analysis of dry acetabulum and iliac bones from anatomy museums in south eastern Nigeria with relation to clinical practice. *Eur J Clin Exp Med*. 2024;22(4):756–762. doi: 10.15584/ejcem.2024.4.10.



Introduction

The hip joint socket, the acetabulum ('vinegar cup'), is a concave hemisphere whose axis is not strictly horizontal but is directed also downwards and slightly anteverted along the axis of the femoral neck. Its inferior margin is lacking, so the vinegar would run out of the cup. Deficiency at the inferior margin is the acetabular notch.^{1,2} The acetabulum is divided into four quadrants as described by Wasielewski et al. by bisecting them with an imaginary line from the anterior superior iliac spine and another line passing through the center of the acetabulum perpendicular to the first line.³ The thickest quadrant is the postero-superior, followed by the postero-inferior, then the antero-superior and the thinnest, the antero-inferior quadrant.³ It is very important to know this as well as the average length of the screws that can be placed safely at various quadrants of the acetabulum during surgery.³

The ilium forms the pelvic brim between the hip joint and the joint with the sacrum; above the pelvic brim it is prolonged, broad and wing-like, for the attachment of ligaments and large muscles.¹ The ilium is divisible into two parts, the body (corpus ossis ilii) and the ala (ala ossis ilii).¹ The following anatomical landmarks are at the anterior border of ala; the anterior superior iliac spine (ASIS) which can be palpated under the skin and the anterior inferior iliac spine (AIIS). Between these iliac spines there is incisure (incisura iliaca anterior). At the posterior border of ala are the posterior superior iliac spine (PSIS) and the posterior inferior iliac spine (PIIS). There is incisure (incisura iliaca posterior) between these spines.⁴

Acetabular morphometric parameters like depth of the cavity, diameter and acetabular notch width in addition to the head of the femur determine the stability of the hip joint.⁵

The average depth of the acetabulum from previous studies ranges from 20 mm to 32 mm.^{2,6-9} The acetabular depth has been considered by many investigators as an important measurement in defining acetabular dysplasia. The acetabulum with depth of less than 9 mm is regarded as acetabular dysplasia.¹⁰ In acetabular dysplasia, there is deficient coverage of the femoral head superolaterally and anteriorly, therefore there is decreased surface area for weight bearing. Excessively deep acetabulum can predispose the person to pincer femoroacetabular impingement syndrome, which will eventually lead to osteoarthritis of the hip joint.¹¹

The diameter of the acetabulum has been documented by previous authors. Ukoha et al. obtained a mean acetabular diameter of 55.8±3.7 mm on the right side and 54.6±3 mm on the left side.⁶ A study done by Chauhan et al. in a North Indian population obtained values of 47.10±2.9 mm on the right side and 47.48±3.05 mm on the left side.¹²

The morphometry of the acetabulum and iliac bones has been shown to vary amongst individuals from different geographic locations or regions, there is also variation amongst individual from different racial groups and ethnicities.^{13,14} Good outcome of total hip replacement surgeries, and pelvic surgeries had been linked to proper understanding of the morphometry of the acetabulum and iliac bones. For instance, it aids in the placement of fixation screws at the right location to avoid damage to adjacent neurovascular structures.¹⁵ Also, the size of the prosthetic cup in total hip replacement should be about the same as the dimensions of the native acetabulum. Knowledge of this morphometry is also applied in implant manufacture and selection for pelvic and hip surgeries. Good understanding of iliac bone morphometry also aids the surgeon to identify important bone landmarks (anterior superior iliac spine, posterior superior iliac spines etc.) during surgeries.¹⁶

Pelvic surgeries and total hip replacement surgeries are presently being done in our environment. These surgeries require acetabular components for the total hip replacement surgeries, special plates and screws for the acetabular reconstruction surgeries. These prosthesis and implants are manufactured with similar morphometries as the native bone. There is paucity of data about acetabular and iliac bone parameters in our environment and no previous study in our environment had established relationship between the depth and diameter of the acetabulum. This study was therefore designed to help in bridging this gap in knowledge.

Aim

This study aims to provide database of the values of acetabular morphometries of people of southeast Nigeria, also to establish a model for the prediction of acetabular diameter from the depth and vice versa. Mean values obtained will be of immense benefit to bioengineers who manufacture acetabular prosthesis and pelvic implants.

Material and methods

The study is a cross-sectional study conducted at the anatomy museums of Departments of Human Anatomy of six universities in the southeastern Nigeria.

Normal adult hip bones without pathology or features of wear and tear from storage and preparation were included in the study. Bones whose epiphyses had not fused were excluded from the study.

All the hip bones in the Anatomy museums which met the inclusion criteria were used for the study.

Ethical clearance was obtained from the Research and Ethics Committee of Enugu State University of Science and Technology. Ethical right permission number is ESUCOM/FBMS/ETR/2022/015.

Electronic Vernier caliper, thin metallic meter rule, examination gloves and markers were used in the study.

Depth of the acetabulum

Figure 1 shows the measurement of depth of the acetabulum. The maximum vertical distance from the deepest point in the acetabular cavity (center of the acetabulum) to the horizontal plane touching the margins of the acetabular cavity. A thin metallic meter rule was kept across the margins of the acetabular cavity and the depth of the acetabulum was measured on the Electronic Vernier caliper using the depth gauge from the deepest point in the acetabulum to the ruler.²



Fig. 1. Measurement of the depth of the acetabulum.

Diameter of the acetabulum

The distance from the junction where anterior iliac margin meets the periphery of the acetabulum to a point on the periphery of the Acetabulum nearest to the ischial tuberosity was measured with Electronic Vernier caliper.¹⁷ This measurement is shown in Figure 2.

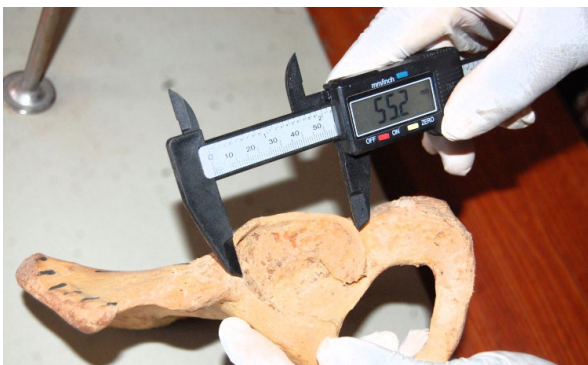

Fig 2. Measurement of the acetabular diameter

Width of the acetabular notch

The distance between the ends of the lunate surface of the acetabulum was measured with an electronic Vernier caliper.¹⁷ This is shown in Figure 3.

Thickness of the acetabulum

The acetabulum was divided into 4 quadrants as was described by Wasielewski.³ This was done by drawing a straight line with meter rule and marker from the anterior superior iliac spine bisecting the acetabulum. Another line, perpendicular to the 1st, through the center

of the acetabulum was drawn. Figure 4 shows measurement of the acetabular wall thickness. These lines divide the acetabulum into 4 quadrants; the anterosuperior, anteroinferior, posterosuperior and posteroinferior quadrants.³ With the aid of an electronic Vernier caliper, the thickness of the acetabulum was measured at a point 2 cm from the rim of the acetabulum in each of the quadrants.



Fig 3. Measurement of the acetabular notch width.

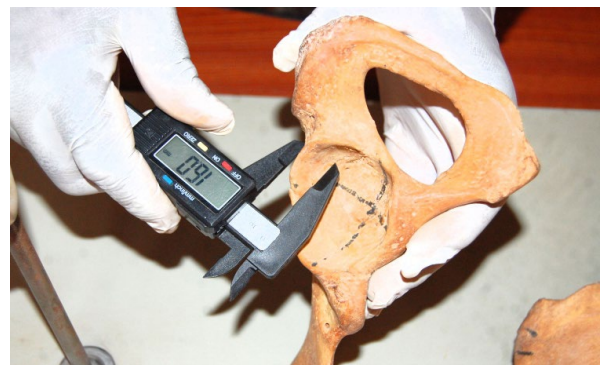

Fig. 4. Measurement of the acetabular wall thickness

Distances between landmarks on the iliac bone

The distances between the following bony landmarks on the iliac bone were measured:

Distance between anterior inferior iliac spine (AIIS) and posterior inferior iliac spine (PIIS). This is shown in Figure 5.

Distance between the posterior superior iliac spine (PSIS) and the anterior inferior iliac spine (AIIS).

Distance between anterior inferior iliac spine (AIIS) and anterior superior iliac spine (ASIS).

Distance between the posterior superior iliac spine (PSIS) and the upper edge of the acetabulum (UEA).

Distance between the anterior superior iliac spine (ASIS) and the nearest edge of the acetabulum (NEA). This is shown in Figure 6.

Statistical analysis

Data was collated and analyzed using IBM SPSS version 26 (Armonk, NY, USA). Descriptive statistics which include means and standard deviations were obtained for continuous variables. Comparison of means was done

using student's t test. *P* value less than 0.05 was regarded as significant. Relationship between diameter and depth of acetabulum was assessed using Pearson correlation. A regression analysis was done to see if the depth of acetabulum can predict the diameter.

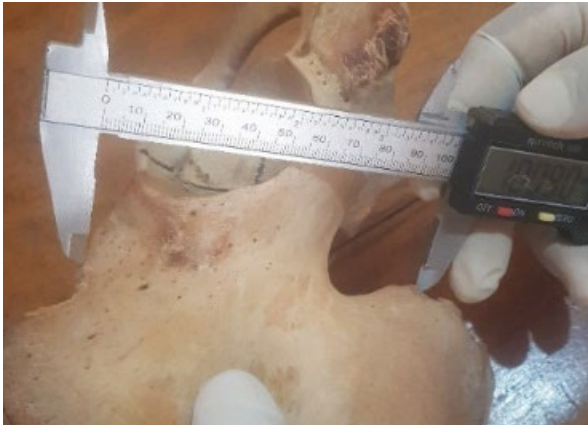

Fig. 5. Measuring the distance between the AIIS and PIIS

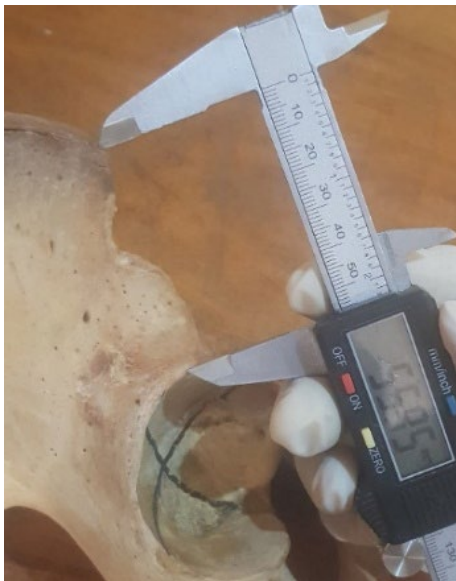

Fig. 6. Measuring the distance between the ASIS and nearest edge of the acetabulum



Fig. 7. Measuring the distance between the ASIS and AIIS

Results

One hundred and forty-eight (148) pelvic bones that met the inclusion criteria were used for the measurements. Right hip bones were 75 in number while left hip bones were 73 in number. Table 1 shows the values of the measured parameters. The mean acetabular depth is 32.10 ± 2.33 mm, the mean acetabular diameter is 53.93 ± 2.74 mm. Mean values of all the parameter are shown in the Table 1.

Table 1. The mean acetabular depth, diameter, notch width, wall thickness, and iliac bone measurements. Measured in millimeters (mm)

	n	Minimum	Maximum	Mean	Std. deviation
Acetabular depth	148	27.4	38.11	32.1	2.33
Acetabular diameter	148	47.7	60.1	53.95	2.74
Acetabular width	148	8.6	35.63	24.3	3.57
Antero-inferior wall thickness	148	2.2	8.48	5.88	1.38
Antero-superior wall thickness	148	8.8	18.42	12.64	1.84
Postero-inferior wall thickness	148	10.4	23.1	15.79	2.07
Postero-superior wall thickness	148	14.68	28.5	19.74	2.18
AIIS-PIIS	148	90.7	130.5	112.91	8.01
PSIS-AIIS	148	116.5	157.1	135.29	8.04
AIIS-ASIS	148	24.33	135.58	34.98	9.55
PSIS-UEA	148	96.44	138.70	119.14	7.83
ASIS-NEA	148	37.30	71.55	55.71	5.6

Table 2 shows there is no significant difference in the mean values of both sides.

Table 2. Comparison of mean parameters between the right and left sides. Measured in millimeters (mm)

	Right Mean \pm SD	Left Mean \pm SD	T	P
Acetabular depth	32.13 \pm 2.43	32.07 \pm 2.24	0.169	0.866
Acetabular diameter	53.86 \pm 2.54	54.04 \pm 2.95	0.382	0.703
Acetabular width	24.56 \pm 3.26	24.04 \pm 3.86	0.887	0.376
Antero-inferior wall thickness	5.82 \pm 1.37	5.94 \pm 1.38	0.517	0.606
Antero-superior wall thickness	12.49 \pm 1.68	12.79 \pm 1.99	0.959	0.339
Postero-inferior wall thickness	15.68 \pm 2.02	15.90 \pm 2.12	0.66	0.51
Postero-superior wall thickness	19.48 \pm 2.42	20.01 \pm 1.88	1.479	0.141
AIIS-PIIS	113.74 \pm 7.32	112.07 \pm 8.62	1.267	0.207
PSIS-AIIS	135.79 \pm 7.39	134.78 \pm 8.68	0.756	0.451
AIIS-ASIS	35.50 \pm 12.76	34.44 \pm 4.27	0.675	0.501
PSIS-UEA	118.69 \pm 7.74	119.59 \pm 7.96	0.706	0.481
ASIS-NEA	55.43 \pm 6.11	55.99 \pm 5.03	0.618	0.538

There is a significant positive linear relationship between the depth of the acetabulum and the diameter of the acetabulum ($r [148]=0.266, p<0.001$).

Table 3 shows the regression model for prediction of diameter of the acetabulum using the depth of the acetabulum. It shows that for every 1 mm increase in the acetabular depth, the acetabular diameter increases by 0.312 times. The equation is "Y = bx + a" where Y =

Acetabular diameter, x = Acetabular depth, b = margin of error = 0.312, a = constant determined to be 43.919.

Table 3a. The regression model for prediction of the diameter of the acetabulum using the depth of the acetabulum (model summary)

Model	R	R square	Adjusted R square	Std. error of the estimate	Change statistics				
					R square change	F change	df1	df2	Sig. F change
1	0.266 ^a	0.071	0.064	2.65396	0.071	11.087	1	146	0.001

a. predictors: (constant), acetabular depth

Table 3b. The regression model for prediction of the diameter of the acetabulum using the depth of the acetabulum (ANOVA)

Model	Sum of Squares	Df	Mean Square	F	Sig.
1 Regression	78.090	1	78.090	11.087	0.001 ^b
1 Residual	1028.350	146	7.043		
Total	1106.439	147			

a. dependent variable: acetabular diameter
b. predictors: (constant), acetabular depth

Table 3c. The regression model for prediction of the diameter of the acetabulum using the depth of the acetabulum (coefficients – the equation is “ $Y = bx + a$ ” where Y = acetabular diameter, x = acetabular depth, b = margin of error = 0.312, a = constant = 43.919)

Model	Unstandardized coefficients		Standardized coefficients	T	Sig.
	B	Std. error	Beta		
1 (Constant)	43.919	3.020		14.541	0.000
1 acetabular depth	0.312	0.094	0.266	3.330	0.001

a. dependent variable: acetabular diameter

Discussion

The difference between the mean values of right and left sides for the depth, diameter, wall thickness and width of the acetabulum including the mean distances of bony landmarks on the iliac bones from this study are not statistically significant, this is similar to findings from other studies.^{1,3,6,18,19-21} This is important especially for patients that will require a second total hip replacement surgery or implant surgery on the opposite side as similar sizes of implants can be kept for the opposite side.

The mean acetabular depth of dry bones in South East Nigeria was higher than what was reported in studies carried out in Indian, Portuguese, Canadian, Chinese and Turkish populations. Gangavarapu et al. and Yuges et al. in separate studies in Indian population obtained values of 24.09±2.69 mm 29.9±0.21 mm respectively, Arsuaga et al. documented a value of 25.1 mm in Portugal.^{8,17,18} Lang documented an acetabular depth of 29±3.8 mm in dry bones in Canada.⁷ Bagei et al. in an acetabular study in Turkey reported mean

depth of 24.87–22.85 mm.²² Zheng et al. documented 19.4±2.21 mm as the value of acetabular depth in Chinese population.²³ A study by Ukoha et al. in Nigeria obtained value of 29.7 mm for the acetabular depth.⁶ These differences may be as a result of the peculiarities in body build/sizes of the different populations involved. For the Chinese, it may be because the study was a CT scan-based study which may not be as accurate as the value obtained by direct measurement. Similar study done in Nigeria also had lower mean value, this may be attributed to the fact that this study is more encompassing, it involved 6 centers in 3 states with more hip bones measured.⁶ This finding is important because it will motivate our local bioengineers to look at the possibility of manufacturing acetabular cups with dimensions similar to acetabulum of the local population.

The mean acetabular diameter of dry hip bones in South East Nigeria is higher than the values reported in 2 separate Indian studies, with reported values of 49.4±3.5 mm and 47.4±0.23 mm.^{17,18} However mean acetabular diameter from this study is lower than 55.2±3.11 reported in China and 55.8±3.7 reported by a previous Nigerian study.^{6,23} Chauhan et al. opined that smaller values of the acetabulum parameters seen in Indians are due to short stature of Indians when compared to Africans.¹² Knowledge of the acetabular diameter of our local population will aid pre-operative surgical planning, by ensuring that sizes of acetabular cups matching the values of native acetabulum of the local population are available.

The mean value of acetabular notch width of acetabulum of dry hip bones in south-east Nigeria was more than that reported for Indian and South Africa populations with mean values of 22.25±2.97 mm and 21.85±3.42 mm respectively.^{17,24} This may be due to racial variations in sizes of bones.

The acetabular wall thickness from this study follows similar pattern as was documented by Wasielewski et al. and Varodompun et al. showing the posterior-superior wall is the thickest with the highest value followed by posterior-inferior wall, then anterior-superior wall and anterior-inferior wall in that order.^{3,15} However, the acetabular wall thickness of hip bones in south-east Nigeria is thicker than what was documented for the Thai population only at the antero-inferior quadrant. The mean value from the other 3 quadrants is less than that of the Thai population. The reported mean values for the Thai population include; 15.16 mm, 3.49 mm, 29.12 mm, and 26.63 mm for the antero-superior, antero-inferior, postero-superior, and postero-inferior quadrants respectively.¹⁵ This finding could be as a result of racial variations, it could also be because the wall thickness from this study was measured 2 cm from the rim while those of the Thais measured from any point on a middle segment between the rim and the center of

the acetabulum. Knowledge of the wall thickness pattern will enable orthopedic surgeons that do hip replacement surgeries to always direct acetabular screws to the postero-superior quadrant.

The mean distances between the AIIS and the PIIS, the AIIS and ASIS, and the ASIS and the nearest edge of acetabulum (NEA) for the Turkish population are 117.51 ± 7.7 mm, 41.46 ± 5.02 mm, and 60.3 ± 5.46 mm respectively.¹⁶ These values are more than that obtained from the present study. However, the mean distance between the PSIS and the UEA of hip bones in south east Nigeria are more than the mean value (106.24 ± 12.63 mm) reported for Turkish population and less than the value (124.9 ± 7.1 mm) documented for USA population.^{16,20} A Chinese study obtained 139.1 ± 5.6 mm as the mean distance between the PSIS and AIIS, this is greater than the value obtained in this study.²¹ All these differences may be as a result of racial variation in the dimensions of the hip bone. Bony landmarks of the iliac bone usually serve as guides to Surgeons. Knowledge of the mean values of distances between these landmarks is very important because it helps surgeons to select and use screws of appropriate length, this is of immense benefit to centers that do not have a C-arm machine for real-time imaging.

There is a significant positive linear relationship between acetabular depth and diameter. Devi et al. reported positive and significant correlation between the depth and diameter of the acetabulum ($r=0.416$ $p<0.001$) in India.²⁵ Aksu et al. in another study on Turkish people reported positive and significant correlation between the depth and diameter of the acetabulum ($r=0.498$ $p<0.001$).²⁶ Mahmut et al. in a radiological study reported a positive significant correlation between the acetabular diameter and depth in males and females.²⁷ However, none of these previous authors proposed a model for predicting acetabular diameter from depth and vice versa. The model equation proposed in this study can be used to predict to some degree of accuracy the acetabular diameter using the depth, especially in some cases of arthroplasty surgeries where the diameter cannot be measured directly due to bony defects in diseased acetabulum. Estimation of the acetabular diameter from the depth will assist the surgeon to have an idea of the size of the acetabular reamer he/she will start with. And the array of sizes of acetabular cups that will be kept in the inventory for the surgery.

Recommendations

The morphometric values obtained in this study will assist Surgeons that do hip and acetabular surgeries in our environment to stock the sizes of implants that matches that of the local population in their inventory. The values obtained can also assist bioengineers that manufacture the implants and prosthesis for hip surgeries to

produce the ones that will match our local population. Surgeons can use the model obtained from this study to predict the diameter of the acetabulum from the depth of the acetabulum and vice versa.

Study limitations

The bones are not stored separately based on sex, hence being unable to discriminate between genders of the bones limited our study.

Conclusion

This study was able to establish the mean acetabular depth, acetabular diameter, acetabular notch width, acetabular wall thickness and distances between bony landmarks of hip bones in south-east Nigeria. There is no statistically significant difference between the mean values of right and left sides. There are variations between the majority of the study means and that from other regions.

There is statistically significant relationship between the depth of the acetabulum and the diameter of the acetabulum. The diameter of the acetabulum can be used to significantly predict the depth of the acetabulum and vice versa.

Acknowledgement

I would like to acknowledge the departments of Anatomy in the universities where this study was carried out for allowing us use the bones in their Anatomy museums for this study. These universities are Enugu state University of Science and Technology, University of Nigeria Enugu Campus, Ebonyi State University Abakaliki, Alex Ekwueme Federal University Ndufu-Alike Ikwo Ebonyi state, Nnamdi Azikiwe University Nnewi Campus Anambra state, Chukwuemeka Odumegwu Ojukwu University Anambra state.

Declarations

Funding

There was no external source of funding.

Author contributions

Conceptualization, H.C.E., E.E., A.U.K., U.E.A., I.I.O., R.T.E. and C.V.A.; Methodology, H.C.E., E.E., A.U.K., U.E.A., I.I.O., R.T.E. and C.V.A.; Software, A.U.K.; Validation, H.C.E., E.E., A.U.K., U.E.A., I.I.O., R.T.E. and C.V.A.; Formal Analysis, A.U.K. and H.C.E.; Investigation, H.C.E. and C.V.A.; Resources, H.C.E., E.E., A.U.K., U.E.A., I.I.O., R.T.E. and C.V.A.; Data Curation, H.C.E.; Writing – Original Draft Preparation, H.C.E.; Writing – Review & Editing, H.C.E., E.E., A.U.K., U.E.A., I.I.O., R.T.E. and C.V.A.; Visualization, H.C.E., E.E., A.U.K., U.E.A., I.I.O., R.T.E. and C.V.A.; Supervision, E.E.; Project Administration, H.C.E., E.E., A.U.K., U.E.A., I.I.O., R.T.E. and C.V.A.

Conflicts of interest

No conflicts of interest

Data availability

Data was readily available during the work hours and work days.

Ethics approval

Ethical approval was obtained from the Research and Ethics Committee of Enugu State University of Science and Technology. Ethical right permission number is ES-UCOM/FBMS/ETR/2022/015.

References

- Sinnatamby CS. *Last Anatomy*, 12th Ed., Churchill Livingstone Elsevier, London, 2011. Pg. 263.
- Khobragade L, Vatsalawamy P. Morphometric study of the depth of acetabulum. *Int J Res Med Sci*. 2017;5(9):3837-3842. doi: 10.12669/pjms.38.8.5915
- Wasielewski RC, Cooperstein LA, Kruger MP, Rubash HE. Acetabular anatomy and transacetabular fixation of screws in total hip arthroplasty. *J Bone and Joint Surg*. 1990;72-A:501-506.
- Soames RW. Skeletal System. In: Williams PL, Bannister LH, Berry MM, et al, editors. *Gray's Anatomy, The Anatomical Basis of Medicine and Surgery*. 38th ed. Churchill Livingstone, 1995; 425-736.
- Ilankathir S, Sudagar M, Rajan T, et al. Morphometric study of acetabulum in adult dry human pelvic bone. *Indian J Anat*. 2019;8(4):289-292.
- Ukoha UU, Umeasalugo KE, Okafor JI, Ndukwe GU, Nzeakor HC, Ekwunife DO. Morphology and morphometry of dry adult acetabula in Nigeria. *Rev Argent Anat Clin*. 2014;6(3):150-155.
- Lang C. Osteometric differentiation of male and female hip bones: An exploratory analysis of some unorthodox measurements. *Canad Rev Phys Anthropol*. 1987;6(1):1-9.
- Arsuaga JL, Carretero JM. Multivariate analysis of the sexual dimorphism of the hip bone in modern human population and in early hominids. *Am J Physical Anthropol*. 1994;93:241-257. doi: 10.1002/ajpa.1330930208
- Kim YH. Relationship between the sphericity of femoral head-acetabulum and the low incidence of primary osteoarthritis of the hip joint in Koreans. *Yonsei Med. J*. 1989;30(3):280-287.
- Saikia KC, Bhuyan SK, Rongphar R. Anthropometric study of the hip joint in northeastern region population with computed tomography scan. *Indian J Orthop*. 2008; 42(3):260-266. doi: 10.4103/0019-5413.39572
- Kassarjian A, Brisson M, Palmer WE. Femoroacetabular impingement. *Eur J Radiol*. 2007;63:29-35. doi: 10.1016/j.ejrad.2007.03.020
- Chauhan R, Paul S, Dhaon BK. Anatomical Parameters of North Indian Hip Joints-Cadaveric Study. *J Anat Soc India*. 2002;51(1):39-42.
- Sano K, Homma Y, Shirogane Y, et al. Acetabular morphological variation in Asian patients with femoral neck fracture: A three dimensional CT-based study. *Injury*. 2022;53(8):2823-2831. doi: 10.1016/j.injury.2022.06.023
- Singh Archana, Gupta R, Singh A. Morphological and morphometric study of the acetabulum of dry human hip bone and its clinical implications in hip arthroplasty. *J Anat Soc India*. 2020;69(4):220-225. doi: 10.4103/JASI.JASI_214_19
- Varodompun N, Thinley T, Visutipol B, Ketmalasiri B, Pattarabunjerd N. Correlation between the acetabular diameter and thickness in Thais. *Journal of Orthopaedic Surgery*. 2002;10(1):41-44.
- Demir MT, Atay E, Guneri B, et al. Morphometric measurement of the hip bone in Turkish adult population. *Kobe J Med Sci*. 2018;64(4):E149-E156.
- Gangavarapu S, Muralidhar RS. The study of morphology and morphometry of acetabulum on dry bones. *Int J Anat Res*. 2017;5(4.2):4558-4562. doi: 10.16965/ijar.2017.395
- Yugesh K, Kumar SS. Morphometric analysis of acetabulum and its clinical correlation in south Indian population. *Int J Appl Res*. 2016;2(6):1011-1014.
- Khaliq S, Qamar A, Khokhar SK, Naseer H. Morphometric study of acetabular depth and coverage and their clinical importance. *Pal J Med Sci*. 2022;38(8):2227-2233. doi: 10.12669/pjms.38.8.5915
- Berry JL, Stahurski T, Asher MA. Morphometry of the supra sciatic notch intrailiac implant anchor passage. *Spine*. 2001;26:143-148.
- Bin L, Jiwei W, Liyan Z, Wei G. Radiographic study of iliac screw passages. *J Orthop Surg Res*. 2014;9:40.
- Bagei UG, Degermenci M, Ucar I, Arslan A, Nisari M. Morphometric evaluation of the acetabulum. *JOSAM*. 2020;4(7):555-557. doi: 10.28982/josam.752997
- Zeng Y, Wang Y, Zhu Z, Tang T, Dai K, Qui S. Differences in acetabular morphology related to side and sex in a Chinese population. *J Anat*. 2012;220(3):256-262. doi: 10.1111/j.1469-7580.2011.01471.x
- Indurjeeth K, Ishwarkumar S, De Gama BZ, Ndlazil Z, Pillay P. Morphometry and morphology of the Acetabulum within black African population of South Africa. *Int J Morphol*. 2019;37(3):971-976.
- Devi BT, Philip C. Acetabulum – morphological and morphometrical study. *RJPBCS*. 2014;5(6):793.
- Aksu F, Gulrizceri N, Arma C, Tetik S. Morphology and morphometry of the acetabulum. *Journal of Dokuz Eylul University Medical Faculty*. 2006;20(3):143-148.
- Mahmut C, Deniz S, Mustafa C, Ismail OY, Evren K, Davut O. Comparison of diameter and depth morphometry in human acetabulum in terms of age and gender: A radiological study. *J Human Anat* 2017;1(2):000109.