



REVIEW PAPER

Łukasz Ożóg ^{1(ABGF)}, David Aebisher ^{2(ABF)}, Zuzanna Bober ^{3(ABF)},
Dorota Bartusik-Aebisher ^{4(GF)}, Wiesław Guz ^{3(F)}, Marian Cholewa ^{1(AF)}

Magnetic Resonance Elastography – noninvasive method to assess liver disease

¹ Department of Biophysics, Faculty of Mathematics and Natural Sciences, University of Rzeszów,

² Department of Human Immunology, Faculty of Medicine, University of Rzeszów

³ Center of Innovative Research in Medical and Natural Sciences, Faculty of Medicine, University of Rzeszów

⁴ Department of Clinical and Experimental Pharmacology, Faculty of Medicine, University of Rzeszów

ABSTRACT

Currently, liver disease is widespread and the awareness of these diseases is low. Early symptoms of liver disease do not necessarily indicate problems with this organ and patients are usually informed of their problems when the stage of the disease is already advanced. Invasive biopsies are the clinical diagnostic method most commonly used in the evaluation of liver disease. A biopsy is associated with a high risk of false results and additional complications. Finding new non-invasive imaging methods has led to the discovery of a new method called Magnetic Resonance Elastography (MRE). This technique allows one to evaluate the mechanical properties of tissues and to distinguish between pathological states. Testing using this technique can be performed on a conventional magnetic resonance system by using few additional components and properly prepared software. Studies have shown that there is a strong correlation between MRE-measured liver stiffness and the degree of fibrosis. MRE is also useful in characterizing liver tumors. Studies show that this technique is highly credible in both health volunteers and patients with liver fibrosis. MRE has tremendous diagnostic potential. The described technique is not currently widely used and has the potential to serve as a safe and accurate alternative in clinical diagnostics in the future.

Keywords. fibrosis, liver stiffness, MRE, magnetic resonance imaging

Introduction

The frequent occurrence of liver disease is a common problem in society. Nationwide Polish studies of the elderly showed that over 37 % of people had Non-Alcoholic Fatty Liver Disease (NAFLD), and the incidence of advanced fibrosis in the general population was 7.79 %.¹

In most cases, people with liver disorders and pathologies are not aware of them at all. The most common diseases affecting the flesh of the liver are acute and chronic hepatitis B and C. Also prevalent are liver cirrhosis such as alcoholic or nonalcoholic fatty liver as well as various types of tumors.²⁻⁵ NAFLD is the most prevalent dis-

Corresponding author: Łukasz Ożóg: E-mail: luozog@ur.edu.pl

Participation of co-authors: A – Author of the concept and objectives of paper; B – collection of data; C – implementation of research; D – elaborate, analysis and interpretation of data; E – statistical analysis; F – preparation of a manuscript; G – working out the literature; H – obtaining funds

Received: 16.01.2017 | Accepted: 14.05.2017

Publication date: June 2017

ease.^{6,7} Liver cirrhosis associated with liver fibrosis is a serious and irreversible disease whose development (in case of early detection and use of appropriate treatment) can be slowed.^{8,9} Liver cirrhosis is a progressive fibrosis of the liver parenchyma which leads to destruction of its structure.¹⁰⁻¹² Early symptoms of liver disease do not indicate problems with this organ. Often, sick people learn about their problem when the stage of the disease is already very high.

Currently, the most popular method for assessing liver disease is invasive biopsy. This method is associated with a high risk of complications.^{13,14} The advantages of biopsy are a direct assessment of the degree of fibrosis and other pathological lesions (presence of fat, iron in the liver, biliary tract disease).^{15,16} A limitation of biopsy is that cirrhosis may not be detected if the liver biopsy specimen is insufficient (too small) or taken from a healthy segment.^{17,18} Biopsy is also associated with a high risk of false positives and additional complications. Another disadvantage is the high cost of performing a liver biopsy. Biopsies require a trained physician and hospitalization is often required.¹⁹⁻²²

The search for new non-invasive imaging methods led to the discovery of a new method called Magnetic Resonance Elastography (MRE).²³ This technique allows one to evaluate mechanical properties of the tissue in vivo and as such, can be used to provide quantitative imaging of stiffness of the liver.²⁴⁻²⁶ This technique was introduced in clinical practice in 2007 and is currently used in more than 600 sites worldwide.²⁷ MRE is currently available in several centers in Poland including the Center for Innovation and Transfer of Natural Sciences and Engineering Knowledge, the University of Rzeszow and the Department of Radiology and Diagnostic Imaging, Nicolaus Copernicus University in Bydgoszcz. This review

describes the MRI technique and its clinical use in liver testing. The topics covered will be NAFLD, liver fibrosis, hepatitis B and C.

MRE of the liver - technique and operation of the system

The liver MRE is a technique that lasts for several minutes and takes place in a lying position. This technique can be used on a conventional MR system. MRE requires the installation of additional equipment to generate mechanical waves and special software. MRE can be divided into three stages: (1) generating mechanical waves in the tissues of interest; (2) use of a special sequence of motion-encoding gradients (MEGs); (3) processing of wave images by means of an automated inversion algorithm and the formation of quantitative images, called elastograms, that depict the stiffness of tissue. In the liver MRI technique, mechanical waves with a frequency of 60 Hz are used.²³ The mechanical properties of liver tissue can be assessed since waves dissipate faster in stiffer tissue than in a normal liver.

Mechanical shear waves are generated by an acoustic driver outside the magnet space. Then the waves are transmitted through the connecting Tube to a disc-shaped passive driver that is placed in contact with the patient body over the liver (Figure 1). An elastic strap is used to ensure continued contact of the passive driver with patient body. Source of elastic waves (active driver) is synced to a MRI sequence from the scanner as described by Venkatesh *et al.*²⁸ The vibrations used in the liver MRE technique are well tolerated and do not affect the patient's comfort.

Measuring liver tissue motion by a passive driver with MRE is based on an MR imaging technique called phase-contrast MRI.²⁹ MR imaging is performing during continuous harmonic motion in the liver tissue, and MEG

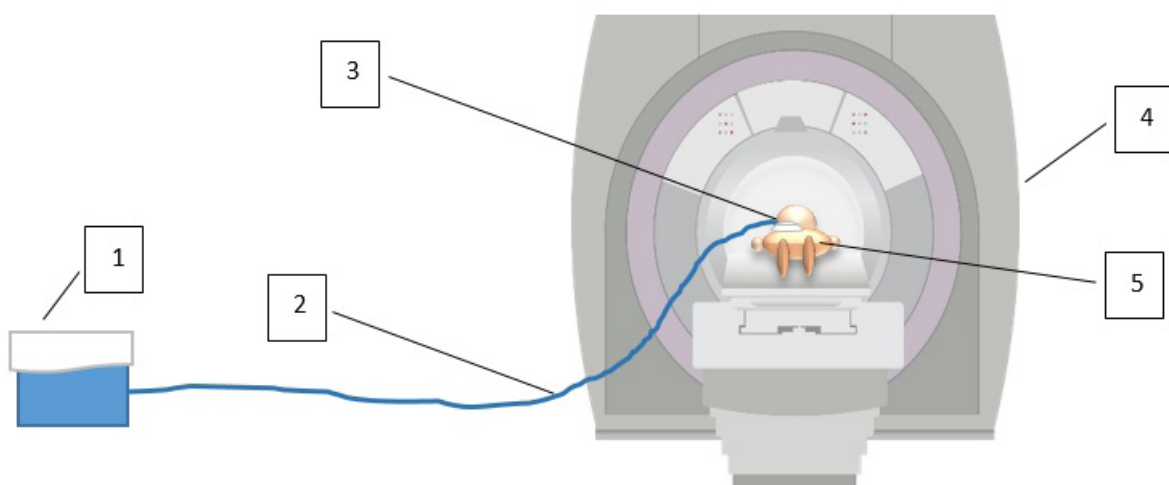


Figure 1. Scheme of a liver MRE system. 1 – Active Driver (source of mechanical waves placed outside the MR room); 2 – Connecting Tube (plastic tube transmitting acoustic vibration); 3 – Passive Driver (non-metallic element with flexible membrane, located on the liver); 4 – magnet; 5 – patient

oscillating at the same frequency. A special MR_Touch sequence is used in the MRE study. In this sequence, 4-8 layers of 6-10 mm thickness are used to produce liver stiffness maps. Each segment/layer requires a breath hold for about 16 seconds. During the breath-holding sequence, images of the pattern of propagating waves in the liver are generated. Upon completion of the study, wave images are automatically processed using an algorithm called an inversion algorithm to generate elastograms which are images of tissue stiffness. These images represent stiffness in units of pascals (Pa). Elastograms can be displayed in a color scale (range 0-8 kPa or 0-20 kPa) or in grayscale.

Stiffness of the liver is assessed by determination of a region of interest (ROI's) on elastograms. The ROI should be placed in the liver area taking into account the offset from the edge of the liver. Stiffness of a healthy liver should not exceed 2.93 kPa.^{24,26,30} In the case of cirrhotic liver the shear waves are longer than the shear waves in the normal liver on wave images. MRE liver also serves as a good tool for characterizing liver tumors. In studies by Venkatesh et al., malignant neoplasms have been shown to be significantly more rigid than benign tumors.³¹

The liver MRE can be made in the majority of patients meeting the requirements of conventional MRI.^{28,32,33} The study should be performed in fasting status, especially in patients with chronic liver disease.³⁴

Detection of Liver Fibrosis using the MRE method

Hepatic fibrosis is easy to recognize using MRE. If the measured stiffness of the liver is greater than 2.93 kPa then more stages of fibrosis can be determined with high sensitivity and specificity.^{26,35} Over the past ten years, more than 1,500 publications have been published describing the use of MRE for the detection of liver fibrosis (Fig. 2).

Liver fibrosis causes mechanical changes in the liver which are characterized by increased stiffness.²² In further advanced stages of fibrosis, the stiffness of the liver parenchyma increases as described in a study by Yin M. et al.²⁶ MRE makes it possible to differentiate patients with advanced degrees of fibrosis from patients with less fibrosis.^{25,26,30,35,36} In addition, this method allows detection of elevated stiffness caused by liver fibrosis, while the use of conventional imaging techniques shows no morphological changes or other anatomical features of liver fibrosis.³⁷ This is an important feature of this method, which can help in a successful diagnosis allowing for early treatment in chronic liver disease. Starting treatment at an early stage often prevents the development of the disease. In studies by Yin et al. from the Mayo Clinic, where 1377 subjects were examined, a high technical efficiency of 94.4 % was demonstrated.³⁸ In addition, mean liver rigidity was significantly higher in patients with advanced fibrosis (stage F3, F4 in METAVIR scale) than in patients with mild to moderate fibrosis (stage F0 to F2). Increased liver stiffness may be caused by conditions unrelated to liver fibrosis. Increased stiffness can affect, among others, acute hepatitis or acute biliary obstruction. Research conducted by Arena et al. have confirmed that acute inflammation of the liver without presence of fibrosis affects liver stiffness.³⁹

Fatty liver, chronic hepatitis and other liver pathology in MRE technique

Nonalcoholic fatty liver disease is becoming more prevalent throughout the world and is often the main cause of chronic liver disease.⁴⁰ This disease is associated with many characteristics such as obesity, insulin resistance, hypertension and diabetes.⁴¹ Many studies have confirmed that MRE liver can accurately distinguish simple fatigue from nonalcoholic steatohepatitis (NASH) and steatohepatitis with fibrosis.⁴²⁻⁴⁴ In addition, the MRE technique is

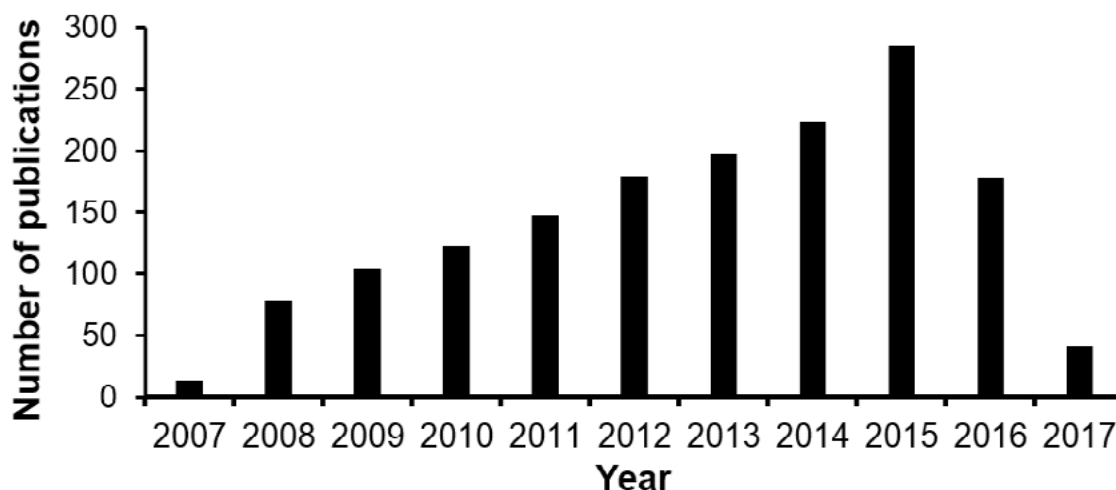


Figure 2. Number of publications in the PubMed National Center for Biotechnology Information (NCBI) for "magnetic resonance elastography liver fibrosis" from 2007 to 2017

helpful in evaluating and treating metabolic disorders. In NAFLD patients, lipid stiffness alone does not have a significant effect on liver stiffness, as shown by Yin M. *et al.*²⁶ However, studies by Chen J. *et al.* show that if the disease progresses to inflammation, the MRE technique allows the stiffness of the liver to be assessed before the onset of fibrosis.⁴²

The Atsushi Nakajima team conducted a study of 142 patients with NAFLD to determine the accuracy of MRE and Transient Elastography (TE) in the classification of fatty liver and liver fibrosis in NAFLD patients.⁴⁵ These studies have shown that the diagnostic accuracy of MRE for liver fibrosis was found to be higher than that of clinical scoring systems and TE. In the study, 7.1 % of patients with advanced fibrosis (F3-F4 stage) were diagnosed by TE as “mild fibrosis” among 127 NAFLD patients, while only 2.8 % patients with advanced fibrosis were diagnosed using MRE as “mild fibrosis” Out of 142 patients with NAFLD. The results show that TE may misclassify patients with advanced fibrosis as compared with MRE.

MRE works very well for patients with chronic hepatitis C. This technique allows you to evaluate the liver's response to treatment. The hepatic stiffness measured by MRE in a patient with chronic hepatitis C can reduce to normal, suggesting proper drug therapy has been used.⁴⁶ Conducting cyclic liver MRE studies for patients with chronic hepatitis allows for the definition of progression or regression of disease.

Liver research conducted by Rohit Loomba *et al.* using MRE in patients with NAFLD has shown that a reduction in body mass index (BMI) of at least 5 % has a significant effect on the reduction of liver stiffness.⁴⁷

MRE studies may be useful in the characterization of liver tumors. Studies conducted by Venkatesh *et al.* in liver examinations using MRE showed that benign liver tumors exhibited lower or similar stiffness to normal hepatic tissue. Malignant lesions, in the majority of cases, are more rigid than those of benign hepatic tumors. In each of 29 patients with malignant tumors, tumor stiffness was more than 5 kPa.⁴⁸ Other studies conducted at the Mayo Clinic, in turn, aimed to establish a correlation of tumor stiffness with histopathology features in patients with hepatocellular carcinoma (HCC). In this study, 21 patients with confirmed HCC were examined using MRE. The obtained data showed that tumor stiffness by MRE may be differentiated by HCC tumor grade.⁴⁹

Summary

MRE is a non-invasive method for evaluating tissue stiffness. In liver MRE studies, it is important to know the presence of conditions that increase stiffness in order to properly interpret the results of MRE in the patients studied. Another important feature of MRE is the possibility of creating a spatial map of liver fibrosis that may be helpful

in biopsy planning.³² Numerous publications have shown that MRE is beneficial as a clinical tool for the diagnosis of hepatic fibrosis. MRE can be particularly important for patients taking medication to inhibit liver fibrosis. This technique is useful in the treatment of chronic liver disease. MRE allows to characterize focal lesions and estimate liver fibrosis. The enormous diagnostic potential of this method, which is outlined in the cited papers, is capable of providing a significant improvement in the diagnosis of liver disease. Continuous research using this technique is aimed at refining it and optimizing this method for subsequent clinical use. In conclusion, more and more evidence indicates that the MRE technique, thanks to the information it brings, can become an important element in the detection and characterization of cancer and the diagnosis of disease.

References

- Hartleb M, Barański K, Zejda J, Chudek J, Więcek A. Non-alcoholic fatty liver (NAFL) and advanced fibrosis in the elderly: results from a community-based Polish survey. *Liver Int.* 2017; DOI:10.1111/liv.13471.
- Craxi A, Antonucci G, Camma C. Treatment options in HBV. *J Hepatol.* 2006;44:77–83.
- Liaw YF, Sung JJ, Chow WC, *et al.* Lamivudine for patients with chronic hepatitis B and advanced liver disease. *N Engl J Med.* 2004;351:1521–31.
- Dienstag JL, McHutchison JG. American gastroenterological association technical review on the management of hepatitis C. *Gastroenterology.* 2006;130:231–64.
- Fernandez-Yunquera A, Rincón D, Salcedo M, Bañares R. Update on the use of direct-acting antiviral agents for the treatment of chronic hepatitis C virus infection. *Rev Esp Quimioter.* 2013;26:189-92.
- Lonardo A, Byrne CD, Caldwell SH, Cortez-Pinto H, Targher G. Global epidemiology of nonalcoholic fatty liver disease-Meta-analytic assessment of prevalence, incidence and outcomes. *Hepatology.* 2016;64:1388-9.
- Younossi ZM, Koenig AB, Abdelatif D, Fazel Y, Henry L, Wymer M. Global epidemiology of nonalcoholic fatty liver disease-Meta-analytic assessment of prevalence, incidence, and outcomes. *Hepatology.* 2016;64:73-84.
- Fowell A, Iredale J. Emerging therapies for liver fibrosis. *Dig Dis.* 2006;24:174–183.
- Zoubek ME, Trautwein C, Strnad P. Reversal of liver fibrosis: From fiction to reality. *Best Pract Res Clin Gastroenterol.* 2017;31:129-41.
- Koyama Y, Xu J, Liu X. New Developments on the Treatment of Liver Fibrosis. *Dig Dis.* 2016;34:589-96.
- Friedman SL. Liver fibrosis- from bench to bedside. *Journal of hepatology.* 2003;38:38–53.
- Lee UE, Friedman SL. Mechanisms of hepatic fibrogenesis. *Best Pract Res Clin Gastroenterol.* 2011;25:195–206.
- Bravo AA, Sheth SG, Chopra S. Liver biopsy. *The New England journal of medicine.* 2001;344:495–500.

14. Ratziu V, Charlotte F, Heurtier A, et al. Sampling variability of liver biopsy in nonalcoholic fatty liver disease. *Gastroenterology*. 2005;128:1898–906.
15. Hernando D, Levin YS, Sirlin CB, Reeder SB. Quantification of liver iron with MRI: State of the art and remaining challenges. *J Magn Reson Imaging*. 2014;40:1003–21.
16. Reeder SB, Cruite I, Hamilton G, Sirlin CB. Quantitative assessment of liver fat with magnetic resonance imaging and spectroscopy. *J Magn Reson Imaging*. 2011;34:729–49.
17. Maharaj B, Leary WP, Naran AD, et al. Sampling variability and its influence on the diagnostic yield of percutaneous needle biopsy of the liver. *Lancet*. 1986;327:523–5.
18. Pagliaro L, Rinaldi F, Craxi A, Di Piazza S, Filippazzo G. Percutaneous blind biopsy versus laparoscopy with guided biopsy in diagnosis of cirrhosis. *Dig Dis Sci*. 1983;28:39–43.
19. Rockey DC, Caldwell SH, Goodman ZD, Nelson RC, Smith AD. Liver biopsy. *Hepatology*. 2009;49:1017–44.
20. Eisenberg E, Konopniki M, Veitsman E, Kramskay R, Gaitini D, Baruch Y. Prevalence and characteristics of pain induced by percutaneous liver biopsy. *Anesth Analg*. 2003;96:1392–6.
21. Fernandez-Salazar L, Velayos B, Aller R, Lozano F, Garrote JA, Gonzalez JM. Percutaneous liver biopsy: patients' point of view. *Scand J Gastroenterol*. 2011;5521:1–5.
22. Tang A, Cloutier G, Szeverenyi NM, Sirlin CB. Ultrasound elastography and MR elastography for assessing liver fibrosis: Part 2, diagnostic performance, confounders, and future directions. *Am J Roentgenol*. 2015;205:33–40.
23. Muthupillai R, Lomas D, Rossman P, et al. Magnetic resonance elastography by direct visualization of propagating acoustic strain waves. *Science*. 1995;269:1854–7.
24. Rouvière O, Yin M, Dresner M, et al. MR elastography of the liver: preliminary results. *Radiology*. 2006;240:440–8.
25. Huwart L, Peeters F, Sinkus R, et al. Liver fibrosis: non-invasive assessment with MR elastography. *NMR Biomed*. 2006;19:173–9.
26. Yin M, Talwalkar J, Glaser K, et al. Assessment of hepatic fibrosis with magnetic resonance elastography. *Clin Gastroenterol Hepatol*. 2007;5:1207–13.
27. Tan C, Venkatesh S. Magnetic Resonance Elastography and Other Magnetic Resonance Imaging Techniques in Chronic Liver Disease: Current Status and Future Directions. *Gut Liver*. 2016;10:672–86.
28. Venkatesh SK, Yin M, Ehman RL. Magnetic resonance elastography of liver: technique, analysis, and clinical applications. *J Magn Reson Imaging*. 2013;37:544–55.
29. Moran PR. A flow velocity zeugmatographic interlace for NMR imaging in humans. *Magn Reson Imaging*. 1982;1:197–203.
30. Huwart L, Sempoux C, Vicaut E, et al. Magnetic resonance elastography for the noninvasive staging of liver fibrosis. *Gastroenterology*. 2008;135:32–40.
31. Venkatesh S, Yin M, Glockner J, et al. MR Elastography of Liver Tumors. *Proceedings 16th Scientific Meeting, International Society for Magnetic Resonance in Medicine; Toronto*. 2008;a.p.2781.
32. Lee V, Miller F, Omary R, et al. Magnetic resonance elastography and biomarkers to assess fibrosis from recurrent hepatitis C in liver transplant recipients. *Transplantation*. 2011;92:581–6.
33. Binkovitz LA, El-Youssef M, Glaser KJ, et al. Pediatric MR elastography of hepatic fibrosis: principles, technique and early clinical experience. *Pediatr Radiol*. 2012;42:402–9.
34. Yin M, Talwalkar JA, Glaser KJ, et al. Dynamic postprandial hepatic stiffness augmentation assessed with MR elastography in patients with chronic liver disease. *AJR Am J Roentgenol*. 2011;197:64–70.
35. Asbach P, Klatt D, Schlosser B, et al. Viscoelasticity-based staging of hepatic fibrosis with multifrequency MR Elastography. *Radiology*. 2010;257:80–6.
36. Wang J, Malik N, Yin M, et al. Magnetic resonance elastography is accurate in detecting advanced fibrosis in autoimmune hepatitis. *World J Gastroenterol*. 2017;23(5):859–68.
37. Rustogi R, Horowitz J, Harmath C, et al. Accuracy of MR elastography and anatomic MR imaging features in the diagnosis of severe hepatic fibrosis and cirrhosis. *J Magn Reson Imaging*. 2012;35:1356–64.
38. Yin M, Glaser K, Talwalkar J, Chen J, Manduca A, Ehman R. Hepatic MR Elastography: Clinical Performance in a Series of 1377 Consecutive Examinations. *Radiology*. 2016;278:114–24.
39. Arena U, Vizzutti F, Corti G, et al. Acute viral hepatitis increases liver stiffness values measured by transient elastography. *Hepatology*. 2008;47:380–4.
40. Loomba R, Sanyal A. The global NAFLD epidemic. *Nat Rev Gastroenterol Hepatol*. 2013;10:686–90.
41. Chalasani N, Younossi Z, Lavine JE, et al. The diagnosis and management of non-alcoholic fatty liver disease: practice Guideline by the American Association for the Study of Liver Diseases, American College of Gastroenterology, and the American Gastroenterological Association. *Hepatology*. 2012;55:2005–23.
42. Chen J, Talwalkar J, Yin M, Glaser K, Sanderson S, Ehman R. Early detection of nonalcoholic steatohepatitis in patients with nonalcoholic fatty liver disease by using MR elastography. *Radiology*. 2011;259:749–56.
43. Loomba R, Wolfson T, Ang B. Magnetic resonance elastography predicts advanced fibrosis in patients with non-alcoholic fatty liver disease: a prospective study. *Hepatology*. 2014;60:1920–8.
44. Kim D, Kim W, Talwalkar J, Kim H, Ehman R. Advanced fibrosis in nonalcoholic fatty liver disease: noninvasive assessment with MR elastography. *Radiology*. 2013;268:411–9.
45. Imajo K, Kessoku T, Honda Y, et al. Magnetic Resonance Imaging More Accurately Classifies Steatosis and Fibrosis in Patients With Nonalcoholic Fatty Liver Disease Than Transient Elastography. *Gastroenterology*. 2016;150:626–37.

46. Venkatesh S, Yin M, Ehman R. Magnetic Resonance Elastography of Liver: Clinical Applications. *J Comput Assist Tomogr.* 2013;37:887–96.
47. Patel N, Hooker J, Loomba R, et al. Weight Loss Decreases Magnetic Resonance Elastography Estimated Liver Stiffness in Nonalcoholic Fatty Liver Disease. *Clinical Gastroenterology and Hepatology.* 2017;15:463–4.
48. Venkatesh S, Yin M, Glockner J, et al. MR elastography of liver tumors: preliminary results. *AJR Am J Roentgenol.* 2008;190:1534–40.
49. Thompson S, Wang J, Chandan V, et al. MR elastography of hepatocellular carcinoma: Correlation of tumor stiffness with histopathology features—Preliminary findings. *Magnetic Resonance Imaging.* 2017;37:41–5.