




CASUISTIC PAPER

Balaji Zacharia ^{1(ABCEFGH)}, Sanoj Paulose ^{2(BCEFGH)}

Idiopathic transient osteoporosis a rare and underdiagnosed entity a case report with a review of the literature

¹ Department of Orthopedics, Government Medical College, Kozhikkode, Kerala, India

² Department of Orthopedics, Jubilee Mission Medical College, Trichur, Kerala, India

ABSTRACT

Introduction. Idiopathic transient osteoporosis of the hip is a rare but underdiagnosed condition. It is common in middle-aged men and pregnant women. The exact etiology is unknown.

Aim. We present a 52-year-old man presented with progressively increasing pain left hip for two months.

Description of the case. The radiograph showed osteoporosis localized to the proximal femur. Magnetic resonance imaging showed bone marrow edema. He was diagnosed as a case of idiopathic transient osteoporosis of the left hip (ITOH) after ruling out other causes. He was treated nonoperatively with analgesics and rest. He was given daily calcium and monthly ibandronate 150mg. His symptoms subsided after 3 months. There was no recurrence of symptoms.

Conclusion. We present this case to describe the clinical, radiological features, diagnosis, and treatment of ITOH. Idiopathic transient osteoporosis is a rare condition. It is often not diagnosed because of a lack of awareness and also being a self-limiting condition. The radiogram may be normal. So a high index of suspicion is needed for its diagnosis.

Keywords. bisphosphonate, idiopathic transient osteoporosis of the hip, regional migratory osteoporosis

Introduction

Idiopathic transient osteoporosis of the hip is a rare but underdiagnosed condition. It is common in middle-aged men and pregnant women. The exact etiology is unknown. The possibilities, like reflex sympathetic dystrophy, small vessel ischemia, obturator nerve compression, intramedullary hypertension, fatty marrow conversion of the proximal femur, and hormonal and chemical change during pregnancy are some of the postulations. It is a self-limiting condition with radiological

evidence of localized osteoporosis around the hip. The diagnosis is usually made by excluding other cases.^{1,2}

ITOH is an uncommon condition. Most cases are misdiagnosed due to a lack of awareness among surgeons.

Aim

Our objective is to describe the clinical features and diagnosis of a 52-year-old man with ITOH along with a literature review. We think this case will be a re-

Corresponding author: Balaji Zacharia, e-mail: balaji.zacharia@gmail.com

Participation of co-authors: A – Author of the concept and objectives of paper; B – collection of data; C – implementation of research; D – elaborate, analysis and interpretation of data; E – statistical analysis; F – preparation of a manuscript; G – working out the literature; H – obtaining funds

Received: 31.08.2020 | Accepted: 20.10.2020

Publication date: December 2020

minder for us to consider transient osteoporosis as a differential diagnosis in adult patients with sudden onset hip pain.

Description of the case

A 52-year-old man presented with gradual onset of progressively increasing pain left hip for two months. There was no history of trauma or constitutional symptoms. No hip ailment in childhood, a non-smoker and non-alcoholic. He had an antalgic gait, with no limb length discrepancy. There was tenderness in the left hip. Range movements were normal. No abnormalities were detected in his routine blood and urine examinations. Radiogram showed osteoporosis in the left proximal femur extending from the head to the trochanteric region, without loss of shape of the femoral head, or subchondral fracture (Fig 1).

An ultrasound scan showed minimal effusion in the left hip. MRI scan revealed diffuse bone marrow edema in the proximal femur with minimal effusion. No evidence of subchondral fracture or collapse of the head. The lesion was hypointense on the T1W image and hyperintense on the T2W image (Fig 2, 3).

An evaluation to rule out a bone metastasis was negative. After excluding other possibilities a diagnosis of ITOH was made. He was treated symptomatically with analgesics and rest. The graduated exercises were done as tolerated by him. He was given daily calcium supplementation with ibandronate 150mg orally once in a month. His symptoms subsided after 3 months and

no recurrence of symptoms or other joint involvement during follow-up was noted.

Discussion

ITOH is a non-destructive and self-limiting condition of the hip. It is a poorly understood and forgotten clinical entity.² It is an uncommon disorder characterized by transient pain and disability with osteopenia in the hip area.³ Curtiss and Kincaid first reported ITOH as 3 cases of hip pain in women in the third trimester of pregnancy in 1959. There was periarticular osteoporosis and no cause was found. The symptoms subsided spontaneously. Later similar cases were described by De Marchi, Santacroce, and Solarino in men also. ITOH is also known as transient bone marrow edema syndrome (TBOS). It may be associated with migrating arthralgia of weight-bearing joints of the lower limbs called regional migratory osteoporosis (RMO).⁴ It is more common in males. Common in the 5th and 6th decades. The patients usually present with a dull aching pain in the groin progressively increasing in intensity over two to three months. There will be difficulty in bearing weight. Wasting of muscles may be present in some cases. Minimal signs will be present during the examination of joints. The range of movements will be full though terminally painful. This discrepancy between disability and lack of signs during examination is an important clue to the diagnosis of ITOH. The symptoms may last for 7 to 9 months thereafter it completely resolve. The natural history of ITOH has 3 phases. The initial phase lasts for

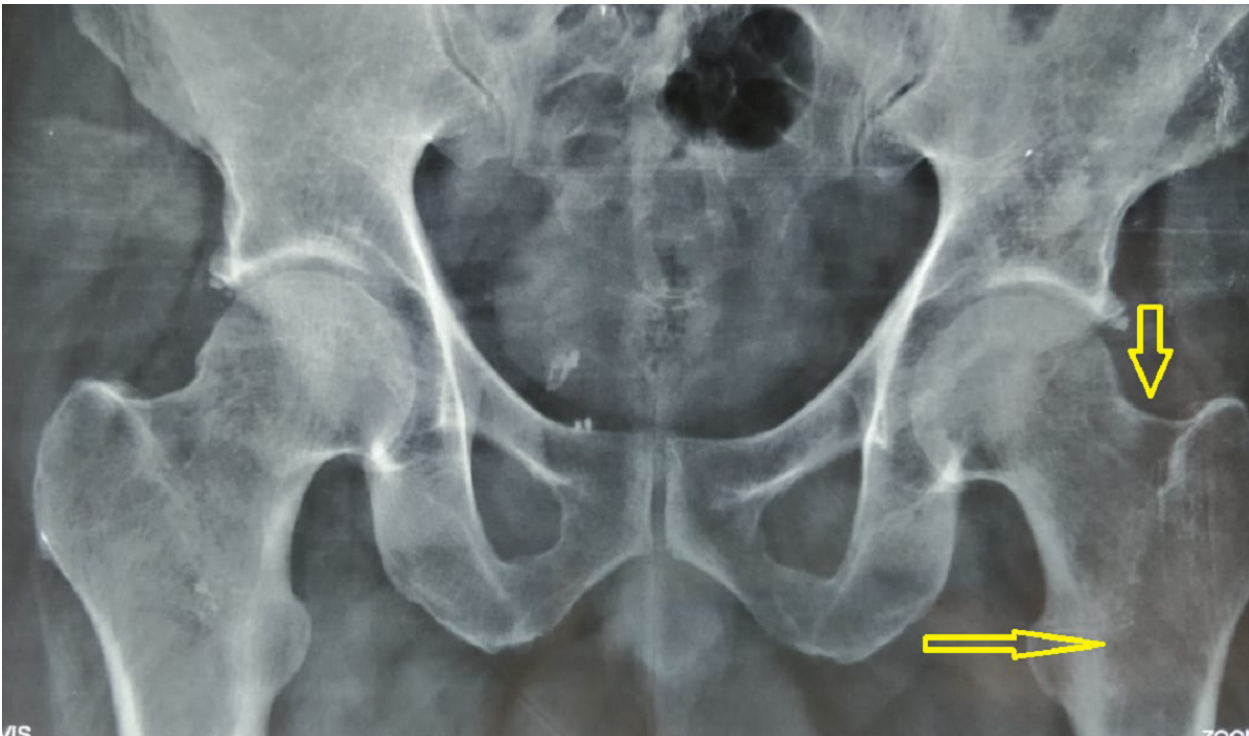


Fig. 1. Radiograph of the pelvis anteroposterior view showing the diffuse osteoporosis in the left proximal femur including head, neck, trochanteric region (arrows)

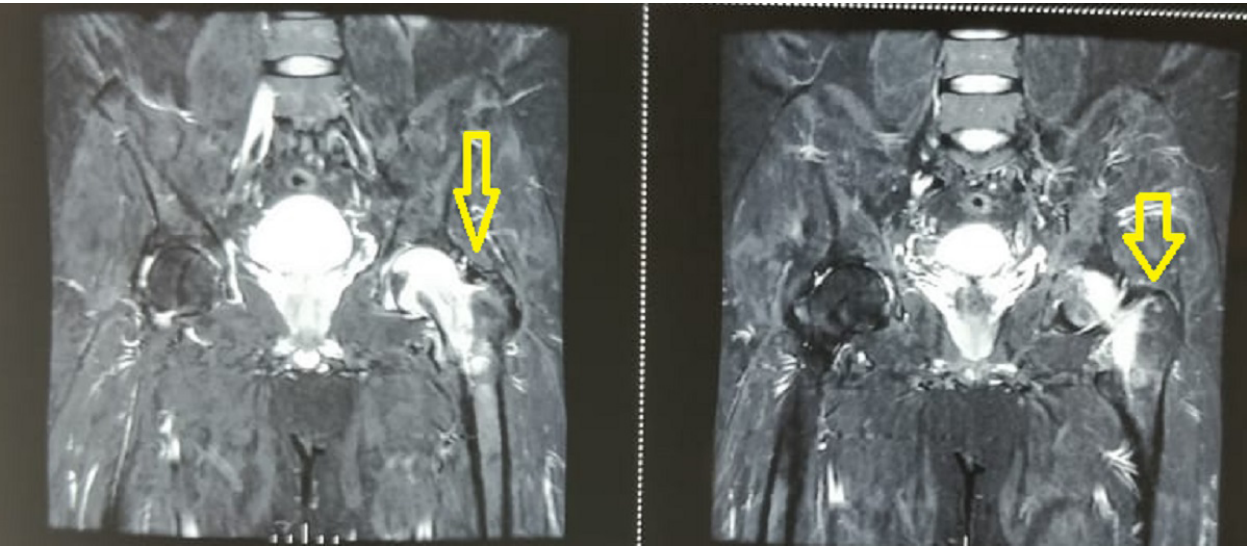


Fig. 2. MRI Scan of the pelvis showing a hyperintense lesion in the head, neck, and trochanteric region of the left hip. There is no evidence of a subchondral fracture of the collapse of the femoral head

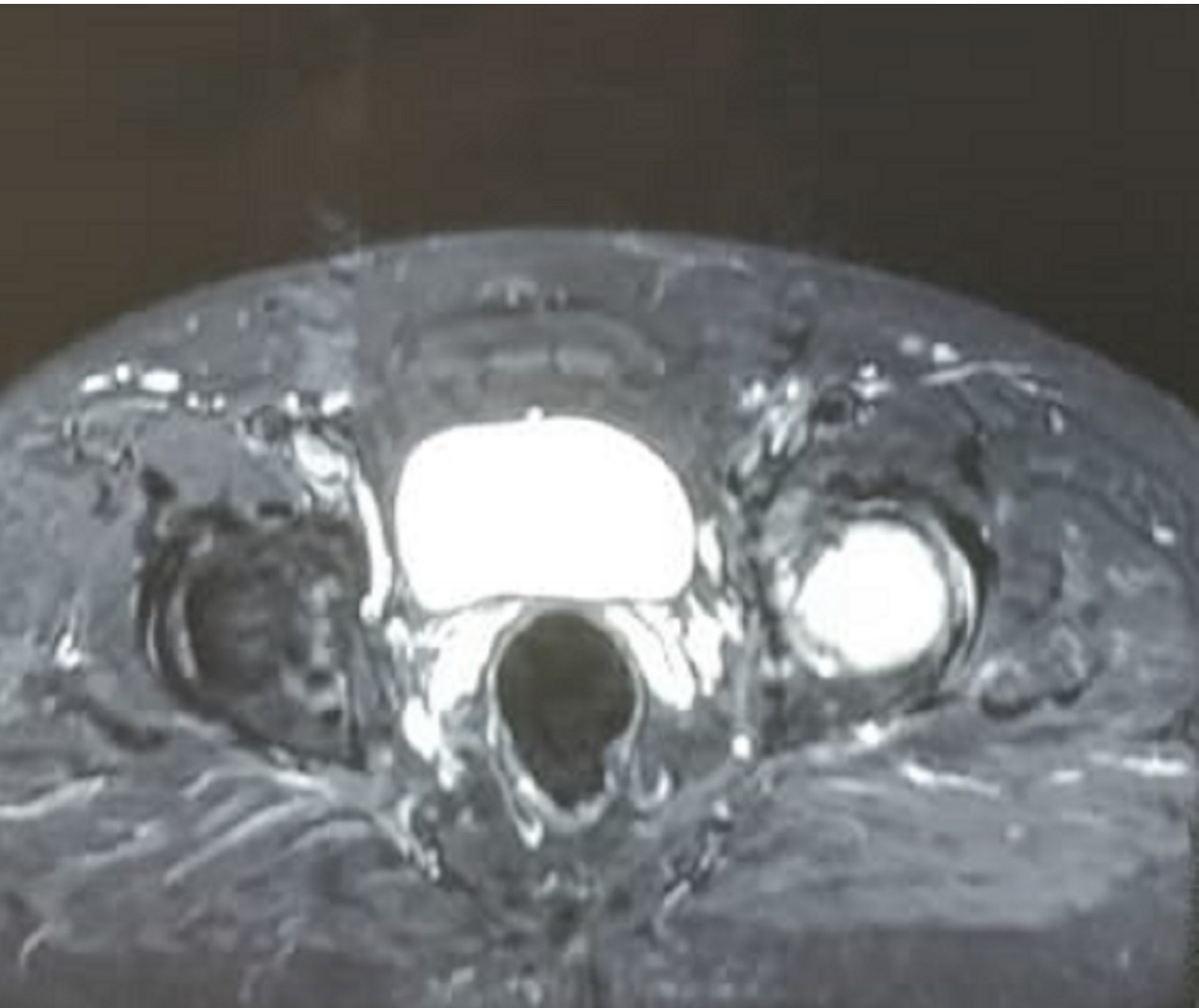


Fig. 3. Transverse MRI image showing a hyperintense lesion in the head, the neck of the left hip

about a month. In this phase, there is a sudden onset of pain and functional limitations. This is followed by plateauing of symptoms for about 2 to 3 months this is the second phase. The third phase is characterized by a gradual decline in symptoms followed by spontaneous regression. It usually takes four months. There is osteopenia during the second phase and bone density returns to normal in the final stage.¹ During pregnancy, it usually starts during the 3rd trimester and subsides by the 3rd month postpartum. It is usually diagnosed as symphysiolysis without tenderness over the pubic symphysis. There can be involvement of other joints in ITOH. It can precede or follow the involvement of the hip. Then it is called RMO. Usually, the migration occurs from proximal to distal joints. Intraarticular migration is described between different compartments of the knee, and between different joints of the foot. Most of the time migration to other joints occurs within a year. Axial skeletal involvement with compression fractures is described in RMO. No involvement of upper limb joints is described in RMO. The diagnosis of ITOH is usually by exclusion.⁴ Rarely fracture of the neck of the femur can occur in ITOH. This complication is commonly seen in transient osteoporosis in pregnancy.⁵

The radiogram shows uniform diffuse radiolucency from the femoral head to the intertrochanteric region. There is no cavitation or subchondral collapse. In some cases, the X-ray may be normal. Rarely acetabulum may show osteoporosis. The joint space is preserved. The loss of subchondral cortical shadow is the pathognomonic sign of transient osteoporosis of the hip in the radiograph.⁶ There is an increased uptake bone scan. Increased uptake is in areas from head to the intertrochanteric region.⁷ Radiological findings can be confused with infection, avascular necrosis, or malignancy. The MRI scan shows bone marrow edema in the proximal femur. There is decreased signal intensity of the bone marrow on T1W images and increased signal intensity relative to normal marrow in T2W images. These are seen both in the epiphysis and metaphysis predominantly along the primary trabeculae. These findings distinguish it from senile osteoporosis and atrophic osteoporosis where there are no signal intensity changes of bone marrow in MRI. Neoplasms and infection can mimic ITOH but they predominantly affect metaphysis. The absence of a well-defined demarcation zone and the area of decreased signal intensity on long SE sequences helps to differentiate it from avascular necrosis in an MRI scan. Bone necrosis with increased turnover and inflammatory changes are seen in bone biopsy.⁸⁻¹⁰

Treatment of ITOH aims at the reduction of pain and disability. Judicious use of NSAIDs protected weight-bearing and graduated physiotherapy is the mainstay of non-operative treatment. Intermittent traction is used to reduce pain and spasm, but not in pregnancy. Oral, intra-

venous, intramuscular bisphosphonates are reported to be helpful. Antiresorptive agents like calcitonin have shown to reduce the duration of illness. Bone sparing steroids like deflazacort were also tried. A prostaglandin analog Ilaprost has shown some promising results.¹¹ Hyperbaric oxygen is also tried in the treatment of ITOH.³ But lack of randomized control trials, small sample size, and the self-limiting nature of the disease question the usefulness of these drugs.¹²⁻¹⁵ Core decompression has shown early relief of pain in ITOH. But it should be used only in prolonged and incapacitating cases.¹⁶ The core decompression can give faster recovery. But many authors suggest it as an unnecessary surgery in ITOH.¹⁷

We presented this case to make us all aware of this condition. Most of the time we miss the diagnosis and the patient gets relief from his symptoms due to self-regression. A strong index of suspicion is required for its diagnosis.

Conclusion

In conclusion, transient osteoporosis of the hip is an underreported entity. Pain and disability out of proportion to clinical signs give us a clue to its diagnosis. More researches in the future may help us to better understand the idiopathic transient osteoporosis of the hip.

References

- Schapira D. Transient osteoporosis of the hip. *Semin Arthritis Rheum*. 1992;22:98-105.
- Vaishya R, Agarwal AK, Kumar V, Vijay V, Vaish A. Transient Osteoporosis of the Hip: A Mysterious Cause of Hip Pain in Adults. *Indian J Orthop*. 2017;51(4):455-460.
- Mutluoglu M, Sonmez G, Sivrioglu AK, Ay H. There may be a role for hyperbaric oxygen therapy in transient osteoporosis of the hip. *Acta Orthop Belg*. 2012; 78(5):685-687.
- Cahir JG, Toms AP. Regional migratory osteoporosis. *Eur J Radiol*. 2008;67(1):2-10.
- Holub A, Marante Fuertes J, Perez Alcantara A. Review of Proximal Femur and Femoral Neck Fractures: Clinical Diagnosis and Management. *Osteoporos Int*. 2018;29 (1 Supp): S556.
- Hayes CW, Conway WF, Daniel WW. MR imaging of bone marrow edema pattern: transient osteoporosis, transient bone marrow edema syndrome, or osteonecrosis. *Radiographics*. 1993;13(5):1001-1011.
- Varenna M, Zucchi F, Binelli L, et al. Intravenous pamidronate in the treatment of transient osteoporosis of the hip. *Bone*. 2002;31(1):96-101.
- Ribera Zabalbeascoa J, Santos Rodas A, Mella Sousa M, et al. Transient osteoporosis of the hip. *International Orthopaedics*. 1999;23(4):244-246.
- Ragab Y, Emad Y, Abou-Zeid A. Bone marrow edema syndromes of the hip: MRI features in different hip disorders. *Clin Rheumatol*. 2008;27(4):475-482.

10. Szwedowski D, Nitek Z, Walecki J. Evaluation of transient osteoporosis of the hip in magnetic resonance imaging. *Pol J Radiol*. 2014;79:36-38.
11. Nicol RO, Williams PF, Hill DJ. Transient osteopenia of the hip in children. *J Pediatr Orthop*. 1984;4:590-592.
12. Guler O, Ozyurek S, Cakmak S, Isyar M, Mutlu S, Mahirogullari M. Evaluation of results of conservative therapy in patients with transient osteoporosis of hip. *Acta Orthop Belg*. 2015;81(3):420-426.
13. Van Wagenen K, Pritchard P, Taylor JA. Transient osteoporosis of the hip: A case report. *J Can Chiropr Assoc*. 2013;57(2):116-22.
14. Pande K, Aung TT, Leong JF, Bickle I. Transient Osteoporosis of the Hip: A Case Report. *Malays Orthop J*. 2017;11(1):77-78.
15. Arayssi TK, Tawbi HA, Usta IM, et al. Calcitonin in the Treatment of Transient Osteoporosis of the Hip. *Semin Arthritis Rheum*. 2003;32(6):388-397.
16. Asadipooya K, Graves L, Greene LW. Transient Osteoporosis of the Hip: Review of the Literature. *Osteoporos Int*. 2017;28(6):1805-1816.
17. Bashairreh KM, Aldarwish FM, Al-Omari AA, et al. Transient Osteoporosis of the Hip: Risk and Therapy. *Open Access Rheumatol*. 2020;12:1-8