



CASUISTIC PAPER

Demystifying the intricacies – a rare report of two cases of biradicular permanent mandibular lateral incisor and their endodontic management

Sameer Makkar , Sandeep Gupta , Aiana Singh , Smriti Rohilla 

Department of Conservative Dentistry and Endodontics, Bhojia Dental College and Hospital, Baddi, Himachal Pradesh, India

ABSTRACT

Introduction and aim. One of the imperative reasons for endodontic failure is an extra or missed root and root canals. Permanent mandibular lateral incisors generally present as monoradicular tooth with one or two canals, but aberrancies in the form of extra root are also rarely seen. There is insufficiency in the literary work regarding the presence of an extra root in permanent mandibular lateral incisor. We hereby report two illustrious cases of biradicular permanent mandibular lateral incisors and their endodontic management and brief review regarding the case reports published so far regarding the existence of an extra root in permanent mandibular lateral incisor in the literature. Also, we intend to apprise the scientific documentation with the aforementioned.

Description of the cases.

Case 1. A twenty-two-year-old male patient of Indian origin was referred to endodontic clinic for intentional root canal therapy. Pre-operative radiograph revealed 32 exhibited aberrancy in the form of an extra root, with normal periodontal structures and bone architecture.

Case 2. A sixty-two-year-old male patient came to the Department of Conservative Dentistry and Endodontics with the chief complaint of pain in the lower anterior tooth region. Radiographic examination revealed root caries on the mesial side and two roots with two canals with bifurcation at the level of middle third of root.

Conclusion. Clinicians should be well prepared in advance for management of any anatomical aberrancy in their clinical practice by having a scrupulous knowledge of root canal system.

Keywords. aberrancy, endo access bur, endodontic treatment, extra root, permanent mandibular lateral incisor, root canal anatomy

Introduction

Missed root(s) and/or root canal(s) is the major reason for endodontic failure as variations in the form of an extra root, root canal and morphology are not uncommon.¹ Such variations can be seen in any tooth of the dental arch with varying degree of incidence. When the clinician is unaware about these anatomic variations, these untreated canals may contain necrotic debris, tissue remnants or organic substrates that

further facilitate growth of pathological microorganisms ultimately leading to endodontic failure. A comprehensive knowledge of tooth roots and root canal morphology is essential for a successful endodontic treatment, which includes pre and intraoperative knowledge about the landmarks as well as any aberrant anatomy facilitating chemo-mechanical cleaning and shaping followed by 3-D obturation of the root canal system.²

Corresponding author: Smriti Rohilla, e-mail: rohilla.smriti1989@gmail.com

Received: 27.06.2023 / Revised: 20.07.2023 / Accepted: 21.07.2023 / Published: 30.12.2023

Makkar S, Gupta S, Singh A, Rohilla S. Demystifying the intricacies – a rare report of two cases of biradicular permanent mandibular lateral incisor and their endodontic management. *Eur J Clin Exp Med*. 2023;21(4):909–913. doi: 10.15584/ejcem.2023.4.9.



Morphologically, permanent mandibular lateral incisor generally presents as a monoradicular tooth with one or two root canals. Various investigators have studied root canal system in mandibular anterior teeth. Earlier it was believed that permanent mandibular incisors have only one root and one root canal. Further studies revealed that 11-68% of mandibular incisors consists of two canals although it converges into one in the apical third.³ Vertucci studied the root canal morphology of 300 mandibular anterior teeth and observed a second canal in 27.5% of mandibular incisors.⁴ Miyashita et al. in another study observed that 12.4% of mandibular incisors contained two canals; however, only 3% had two foramina.⁵ Saati S et al. studied CBCT scans of 207 patients to evaluate the morphology of their mandibular central and lateral incisors. They found that all mandibular central and lateral incisors were single-rooted and 78.2% of all mandibular lateral incisors had one canal.⁶ Mashyakhly studied CBCT images of 822 well-developed mandibular incisors of 208 patients and found that two canals appeared in 26.3% of mandibular central incisors, 30.8% of lateral incisors, and 28.6% of all the 822 mandibular incisors.⁷ However, there is a paucity in the literature regarding the presence of an extra root in permanent mandibular lateral incisor. Scientific literature shows only four such cases have been reported literature regarding the presence of an extra root in Permanent Mandibular Lateral Incisor.⁸⁻¹¹

Hence, clinicians must be aware of the possible morphological variations in permanent mandibular lateral incisor with respect to number of roots and root canals.

Aim

This article, therefore, presents a fortuitous presence of an extra root in permanent mandibular lateral incisor and its endodontic management in two different cases.

Description of cases

Case 1.

A twenty-one-year-old male patient of Indian origin was referred to endodontic clinic from the Department of Prosthodontics for the intentional root canal treatment. The chief complaint of the patient was missing lower anterior teeth that he lost due to accident two years back and wanted to replace them. Patient's medical history was non-contributory. Clinical examination revealed missing mandibular left and right central incisor; normally placed 42 and rotated 32 with absence of any tenderness on percussion and mobility; and normal response to thermal and electric pulp sensitivity tests. Pre-operative radiograph revealed 42 with single root and root canal but 32 exhibited aberrancy in the form of extra root, with normal periodontal structures and bone architecture (Fig. 1a). The diagnosis of normal pulp with normal apical tissues in 42 and 32 was made. Treatment

plan was formulated, and the patient was advised for intentional root canal treatment in 42 and 32 followed by prosthetic rehabilitation.

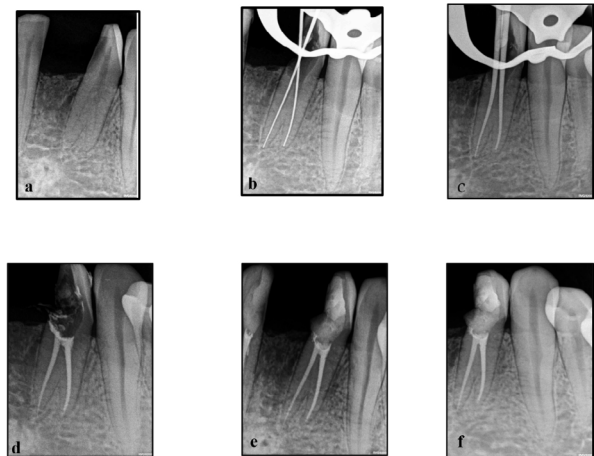


Fig. 1. Radiographic records: preoperative radiograph (a), working length determination (b), master cone (c), post obturation (d), post endodontic restoration (e), follow up (f)

On the day of appointment after taking consent, under proper sterilization protocol, the tooth was anesthetized with 2% lignocaine (LIGNOCAD ADR, Cadila Pharmaceuticals) containing 1:200000 epinephrine solution followed by rubber dam isolation (Coltene Rubber Dam Kit Hygenic). Endodontic access cavity was prepared using an Endo Access bur (Maillefer-Dentsply, Switzerland) using a high-speed handpiece (NSK, Chicago, IL, USA). After deroofting, two canal orifices were located with DG 16 endodontic probe (Hu-Friedy) i.e., buccal and lingual canal. Canal patency was validated using No. 10 K file and No. 8 K file (Mani, Inc., Tochigi, Japan) and pulp was extirpated using barbed broaches. Working length determination (Fig. 1b) was done by means of radiovisiography and confirmed by apex locator (buccal canal: 21.5 mm and lingual canal: 20 mm) to bring off more predictable treatment outcomes. Thorough Cleaning and shaping of the root canals were done using hyflex (Coltene endo) files followed by sequential irrigation of the root canals using 5.25% sodium hypochlorite (Coltene CanalPro NaOCl), 17% EDTA (Coltene CanalPro) and saline. The canals were dried using sterilized absorbent paper points (Coltene Hygenic Spectra Point Absorbent Paper Points), obturation was done by cold lateral condensation technique using seal-apex (Kerr Endodontics) as a sealer (Fig. 1c and Fig. 1d) and temporization was done with Cavit G (3M ESPE, Seefeld, Germany). RVG (Acteon Satelec Sopix) was taken at each step for confirming working length, master cone and subsequently obturation. Post endodontic restoration was done with nanocomposite resin (Ivoclar Tetric N-Ceram) (Fig. 1e) but further the contact was lost due to COVID-19. Patient was then tried to be con-

tacted later and a follow up IOPA was procured from the patient after almost 2 years. This case report has been prepared according to the PRICE2020 Guidelines.¹³

Case 2.

A sixty-two-year-old male patient came to the Department of Conservative Dentistry and Endodontics with the chief complaint of pain in the lower anterior tooth region. On clinical examination, 32 showed root caries on mesial side, elevated response to thermal and electric pulp sensitivity tests whereas it was not tender on percussion. Radiovisiography revealed two roots with two canals that is bifurcation at the level of middle third of root, with normal periodontium (Fig. 2a). Hence, a diagnosis of symptomatic irreversible pulpitis with normal apical tissues in 32 was made. Hence, root canal treatment was advised and explained to the patient.

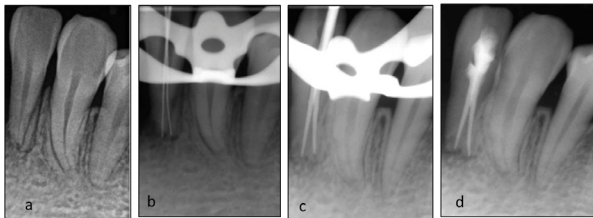


Fig. 2. Radiographic records: preoperative radiograph (a), working length determination (b), master cone (c), obturation with post endodontic restoration (d)

On the day of the procedure, informed consent was taken and the tooth was anaesthetized with 2% lignocaine containing 1:200000 epinephrine solution (LIGNOCAD ADR, Cadila Pharmaceuticals) followed by rubber dam isolation (Coltene Rubber Dam Kit Hygenic). Endodontic access cavity was prepared using an Endo Access bur (Maillefer-Dentsply, Switzerland) using a high-speed handpiece (NSK, Chicago, II, USA). The two canal orifices were located with DG 16 endodontic probe (Hu-Friedy) i.e., buccal and lingual canal. Subsequent to irrigation with sodium hypochlorite, 15 k-file (Mani, Inc., Tochigi, Japan) was used with watch winding motion to create a glide path for both the canals. Working length (Fig. 2b) was established with RVG (Acteon Satelec Sopix) in conjunction with electronic apex locator (buccal=17 mm; lingual=17.5mm). Cleaning and shaping of the root canals were done with (Coltene Gen Endo file system) along with constant irrigation using 5.25% sodium hypochlorite (Coltene CanalPro NaOCl), 17% EDTA (Coltene CanalPro) and saline. Calcium hydroxide as an intra canal medicament was placed for 7 days and patient was recalled.

On the next appointment, the intra canal medicament was removed by irrigating the canal with 5.25% sodium hypochlorite (Coltene CanalPro NaOCl), 17%

EDTA (Coltene CanalPro) and saline along with instrumentation. The canals were dried using sterilized absorbent paper points (Coltene Hygenic Spectra Point Absorbent Paper Points) followed by obturation with gutta percha points and AH plus sealer (Figure 2c and Figure 2d). Post endodontic restoration was done with nanocomposite resin (Ivoclar Tetric N-Ceram) (Fig. 2d). Follow up taken telephonically for any signs and symptoms at 3 months and 6 months as patient had shifted to his native place due to COVID- 19. Follow up IOPA could not be obtained as patient had shifted to his native which is a very remote area. This case report has been prepared according to the PRICE2020 Guidelines.¹³

Discussion

Successful endodontic treatment depends upon requisite knowledge of the normal morphology and variations of the external as well as internal anatomy of the root canal system. Various studies have shown data regarding aberrancies in the form of extra roots and root canals, deltas, fins, calcifications, multiple foramina etc. in the dental arch are not infrequent.¹² For accurate diagnosis, proper clinical and radiographic examination with varying angles should be undertaken. It is essential that clinicians should have the knowledge about the clinical and radiographic signs that may suggest the presence of extra root.

According to literature search, various studies have been done to determine the internal as well as external anatomy of mandibular lateral incisors but very few cases have been reported so far regarding the presence of an extra root in permanent mandibular lateral incisor (Table 1).⁸⁻¹¹ We are fortunate enough to encounter two such noteworthy cases in our endodontic practice and also intend to add to the scientific literature.

Table 1. Case reports published so far regarding presence of extra root in permanent mandibular lateral incisor

S.No.	Author's Name and Year	Journal	No. of tooth reported
1.	Slowey, 1979	<i>Dental Clinics of North America</i>	1
2.	Loushine et al., 1993	<i>Journal of Endodontics</i>	1
3.	Mahajan et al., 2016	<i>International Journal of Medical and Dental Sciences</i>	1
4.	Aggarwal, 2016	<i>Journal of Natural Science, Biology, and Medicine</i>	1

Such anatomical variations in the form of extra roots and root canals can be attributed to genetic as well as racial variations and diagnostic techniques used. According to Weine et al, the present cases demonstrate Type III (two separate as well as completely distinct canals run from the pulp chamber to the root apex).¹⁴ According to Ahmed et al. the tooth of concern presents ²32 B¹ L¹ configuration. As a corollary, a clinician must possess good

clinical skills and treat each tooth assuming to be having complex anatomy as a part of normality.¹⁵

Two roots may be seen separately in the radiograph when bifurcation is present either in the cervical or middle third of the root and is not present in the line of the x-ray beam or the tooth is rotated as seen in case 1. Similarly, bifurcation at the level of middle third of root with normal periodontium was noted in case 2 suggesting the presence of an extra root. The presence of continuous bleeding in teeth with pulpitis or normal pulp despite complete cleaning and shaping can suggest the presence of extra canals and the feeling of a “catch” on the canal wall during instrumentation of a wide and unobstructed main canal is indicative of same. Whereas in cases with necrotic pulps or pulpless teeth, inconsistent apex locator readings, the presence of an apical rarefaction and the offcentre location of an endodontic file in the radiograph indicates the presence of an extra root.¹⁶

At times it is imperative to detect such morphological and anatomic variations before starting the treatment to avoid any iatrogenic errors. It is also essential to modify access preparation as inadequate access opening into the tooth leaves a lingual shelf of dentine over the second (usually the lingual) canal.¹⁷ Magnification using loupes and dental operating microscopes can be adjunct during endodontic therapy procedure. CBCT can be advised before or/and during the treatment procedure as it could be helpful in assessing the difficulty of the case and enhancing clinician’s ability to correctly diagnose and execute a good endodontic therapy.

Conclusion

The present case reports highlight that the clinician should be aware of the fact that even the routine cases might have some deviations from the usual and should always be attentive to detect anatomic anomalies. Radiographs that are taken at different angles and Magnification using loupes and dental operating microscope can be a helping hand in locating extra root canal(s) to confirm any deviation for the normal root canal morphology. Patience, knowledge and judicious planning are the keys for successful endodontic treatment.

Declarations

Funding

This research did not receive any specific grant from funding agencies in the public, commercial, or not-for-profit sectors.

Author contributions

Conceptualization, S.G. and S.R.; Methodology, S.M.; Software, A.S.; Validation, S.M., S.G. and S.R.; Formal Analysis, S.M.; Investigation, S.R. and A.S.; Resources, S.R. and A.S.; Data Curation, A.S.; Writing – Original Draft Preparation, S.R.; Writing – Review & Editing,

S.M. and S.G.; Visualization, S.G.; Supervision, S.M.; Project Administration, S.G. and S.R.

Conflicts of interest

The authors display no conflicts of interest.

Data availability

Data is available according to policy of the journal.

Ethics approval

Informed written consent was taken from the patients.

References

- Wein F. *Endodontic therapy*. 6th ed. Boston, MA, USA: Mosby; 2004.
- Mukhaimer RH, Jarbawi M. Radiographic study of the root canal system of mandibular incisors in Palestinian population. *Open Journal of Stomatology*. 2013;03(08):452-456. doi: 10.4236/ojst.2013.38075.
- Ingle JI. A standardized endodontic technique utilizing newly designed instruments and filling materials. *Oral Surg Oral Med Oral Pathol*. 1961;14:83-91. doi: 10.1016/0030-4220(61)90477-7
- Vertucci FJ. Root canal anatomy of the mandibular anterior teeth. *J Am Dent Assoc*. 1974;89(2):369-371. doi: 10.14219/jada.archive.1974.0391
- Miyashita M, Kasahara E, Yasuda E, Yamamoto A, Sekizawa T. Root canal system of the mandibular incisor. *J Endod*. 1997;23(8):479-484. doi: 10.1016/s0099-2399(97)80305-6
- Saati S, Shokri A, Foroozandeh M, Poorolajal J, Mosleh N. Root morphology and number of canals in mandibular central and lateral incisors using cone beam computed tomography. *Braz Dent J*. 2018;29(3):239-244. doi: 10.1590/0103-6440201801925
- Mashyakhy M. Anatomical analysis of permanent mandibular incisors in a Saudi Arabian population: An in Vivo cone-beam computed tomography study. *Niger J Clin Pract*. 2019;22(11):1611. doi: 10.4103/njcp.njcp_291_19
- Slowey RR. Root Canal Anatomy Road Map to Successful Endodontics. *Dent Clin North Am*. 1979;23(4):555-573. doi: 10.1016/s0011-8532(22)03170-6
- Loushine RJ, Jurcak JJ, Jeffalone DM. A Two-rooted mandibular incisor. *J Endod*. 1993;19(5):250-251. doi: 10.1016/s0099-2399(06)81302-6
- Mahajan P, Grover R, Bhandari SB, Monga P, Keshav V. Management of Mandibular Lateral Incisor with Two Roots: a Case Report. *International Journal of Medical and Dental Sciences*. 2016;5(1):1093-1097. doi: 10.19056/ijmd-sjssmes/2016/v5i1/83583
- Aggarwal K. Mandibular lateral incisor with Vertucci Type IV root canal morphological system: A rare case report. *J Nat Sci Biol Med*. 2016;7(1):101. doi: 10.4103/0976-9668.175103
- Mauger MJ, Schindler WG, Walker WF. An evaluation of canal morphology at different levels of root resection in

- mandibular incisors. *J Endod.* 1998;24(9):607-609. doi: 10.1016/s0099-2399(98)80120-9
13. Nagendrababu V, Chong BS, McCabe P, et al. PRICE 2020 guidelines for reporting case reports in Endodontics: a consensus-based development. *Int Endod J.* 2020;53(5):619-626. doi: 10.1111/iej.13285
 14. Weine FS, Healey HJ, Gerstein H, Evanson L. Canal configuration in the mesiobuccal root of the maxillary first molar and its endodontic significance. *Oral Surg Oral Med Oral Pathol.* 1969;28(3):419-425. doi: 10.1016/0030-4220(69)90237-0
 15. Ahmed H, Aziz Z a. CA, Azami NH, et al. Application of a new system for classifying root canal morphology in undergraduate teaching and clinical practice: a national survey in Malaysia *Int Endod J.* 2020;53(6):871-879. doi: 10.1111/iej.13271
 16. Gelda A, Saraf PA, Patil TN, Malu A. Endodontic Management of Mandibular Incisors with Multiple Canals Using Cone-beam Computed Tomography – A Case Series. *Journal of Research and Advancement in Dentistry.* 2021;12(5):285-290. doi: 10.53064/jrad.2021.12.5.57
 17. Rankine-Wilson RW, Henry P. The bifurcated root canal in lower anterior teeth. *J Am Dent Assoc.* 1965;70(5):1162-1165. doi: 10.14219/jada.archive.1965.0189