

This is a provisional PDF only. Copyedited and fully formatted version will be made available soon.

Authors: Richa Khandelwal, Mary Jenifa Tigga, Rajashekar Metri, Anand Deshpande, Tarun

Article type: Original Article

Received: 6 December 2023

Accepted: 2 February 2024

Published online: 13 February 2024

eISSN: 2544-1361

Eur J Clin Exp Med

doi: 10.15584/ejcem.2024.2.15

Comparative study of pterygium excision with suture and sutureless conjunctival autograft

Richa Khandelwal, Mary Jenifa Tigga, Rajashekar Metri, Anand Deshpande, Tarun

Ophthalmology Department Shri Shankaracharya Institute of Medical Sciences, Bhilai, Chhattisgarh, India

Corresponding author: Richa Khandelwal, e-mail: richa28071996@gmail.com

ORCID

RK: <https://orcid.org/0009-0000-9284-0389>

ABSTRACT

Introduction and aim. This is a prospective interventional study to compare corneal astigmatism before and after pterygium excision with conjunctival autograft, to determine the difference in mean corneal curvatures before and after pterygium excision, to evaluate the safety and efficacy of autologous blood technique, and sutured conjunctival autograft for primary pterygium.

Material and methods. Patients were divided into group A – pterygium excision+sutured conjunctival limbal autograft and group B – pterygium excision+autologous conjunctival limbal autograft under local anesthesia. The preoperative and post operative K1 and K2 values and BCVA were noted.

Results. There was statistically significant reduction in mean astigmatism at each post operative follow up in group A at 1 week ($p=0.0249$), 2 weeks ($p=0.004$), 1 month ($p=0.0031$) and at 3 months ($p=0.0009$) and similarly in group B post operative follow up at 1 week ($p=0.0011$), 2 weeks ($p=0.0021$), 1 month ($p=0.0009$) and at 3 months ($p=0.0003$).

Conclusion. Pterygium surgery decreases the cylindrical error and reverts corneal curvatures to normal, thus improving subjective visual acuity. Astigmatism produced by the pterygium is reduced after surgery. We found autologous conjunctival autograft is superior than sutured conjunctival autograft. Pterygium causes astigmatism depending upon the size of pterygium it should be surgically removed to prevent obstruction in the vision.

Keywords. astigmatism, autologous blood conjunctival autograft, pterygium

Introduction

Pterygium was derived from the Greek word 'Pterygos' which means wing. It is a triangular, wing-shaped, fibrovascular, degenerative, hyperplastic proliferative tissue growing from the conjunctival limbal area onto

the cornea.¹ Pterygia usually develops in the interpalpebral space with a greater number occurring medially than temporally.² The pterygium is made up of cap, head, neck and body. The body extends from the limbus to the bulbar surface. The neck being the narrowest portion of tissue overlies the limbus and extends onto the peripheral cornea. The central extension of fibrovascular tissue is the head. A white grey avascular subepithelial cap is called as stocker line.² It results in cosmetic problems, decrease in visual acuity secondary to astigmatism and blockage of optical axis. When pterygium is small there is only slight irritation in the periods of inflammatory engorgement.³ The progression of a pterygium onto the cornea can cause significant corneal distortion and corneal astigmatism.⁴ When pterygium involves the pupillary aperture, obstruction of vision occurs in the peripheral field and later in the central. Advanced cases of pterygium which encroaches onto the cornea may cause visual loss secondary to:

1. loss of corneal transparency in the visual axis,
2. irregular corneal astigmatism (localized flattening).

Induced astigmatism is due to pooling of tears over the pterygium apex or due to mechanical traction of the pterygium leading to tractional corneal flattening.² An advanced pterygium can produce changes in corneal curvature and refractive state before entering the optical zone, which can cause visual impairment.

Grades of pterygium:⁵

Grade-I: Crossing the limbus but not reaching the pupil margin (<2mm)

Grade-II: Crossing the limbus and reaching up to the pupil margin (2–4 mm)

Grade-III: Reaching beyond the pupil margin (involving the visual axis) (>4 mm)

Aim

The aim of the study was to determine the difference in mean corneal astigmatism before and after pterygium excision. Moreover, we evaluated the safety and efficacy of autologous blood technique and sutured conjunctival autograft for primary pterygium.

Material and methods

The prospective interventional study was done in Shri Shankaracharya Institute of Medical Sciences, Bhilai, C.G. The study period was June 2022 to March 2023. In this study total 58 patients with primary pterygium of age more than 30 years who attended the Ophthalmology Out Patient Department who were suffering from primary pterygium were taken after getting permission from ethical committee of college (SSIMS/EC/2022/21).

Inclusion criteria were as follows: primary pterygium and age more than 30 years.

Participants with recurrent pterygium, pseudo-ptyerygium, surface disorders, cases with serology positive for HIV and hepatitis B were excluded from the study.

All the patients with primary pterygium who attended ophthalmology department were selected. Written informed consent was taken. Thorough examination of the patient in terms of visual acuity, slit – lamp examination of anterior segment, posterior segment examination by direct and indirect ophthalmoscopy was done. Data was collected and patients were ruled out according to exclusion criteria. Before surgery the blood sample for random blood sugar, viral markers were sent.

The patients were randomly divided into two groups. All the surgeries were done by a single surgeon.

Group A – had undergone pterygium excision+sutured conjunctival limbal autograft under local anesthesia.

Group B – had undergone pterygium excision+autologous conjunctival limbal autograft under local anesthesia.

The preoperative and post operative K1 and K2 values and best corrected visual acuity (BCVA) was noted.

Follow up was done on day 1 (D1), day 7 (D7), day (D14), 1 month, 3 months.

On each visits patients were examined for watering, foreign body sensation (Fb), pain and graft stability.

Operative procedure

Eye was painted with 5% povidone iodine and draped. Patient was anesthetized by infiltration of 2% xylocaine. Then the small conjunctival incision on neck of pterygium was made and dissected close to limbus separation of underlying subconjunctival growth was done. The tenon's capsule was dissected. Removal of the pterygium was done. A thin tenon's free conjunctival autograft was taken from superiotemporal quadrant. Gentian violet was used to outline the conjunctiva to be harvested measure by Castro Viejo caliper. The donor area should be 2 mm larger than the bare sclera as the larger graft takes care of graft shrinkage in post operative period ⁶. The limbal edge of the graft should be denoted with specific marks in order to identify the edge. The conjunctival auto graft was then harvested by undermining and careful dissection with blunt Wescott scissors. The free conjunctival auto graft was positioned over the area of bare sclera. Maintaining the limbus to limbus and epithelial-side-up configuration keeping the distance of 0.5 mm to 1 mm from limbus to include the limbal stem cells.⁷ The autograft was then sutured to the underlying sclera at the limbus and to the cut conjunctival edges with 10-0 Vicryl sutures in group A where as in group B the autograft was positioned over the bare sclera and it gets adhered by autologous blood. The graft harvest site does not require closure and will re-epithelialize on its own. Postoperatively, topical steroids and antibiotics were employed at the rate of 4 times a day, and tapering over 4 weeks depending on degree of inflammation and post-operative course.

Results

Total of 58 eyes were included in study among them 28 was in group A and 30 was in group B. Location of pterygium in each group in which majority of location is Nasal (left eye 8 to 10 o'clock and in right eye 2 to 4 o'clock approximately) with 96.4% and 96.7% in group A and group B respectively.

Table 1. Grading of pterygium

Grading of pterygium	Group A		Group B	
	Number of eyes	Percentage	Number of eyes	Percentage
I	4	14.3	5	16.7
II	18	64.3	21	70
III	6	21.4	4	13.3
Total	28	100	30	100

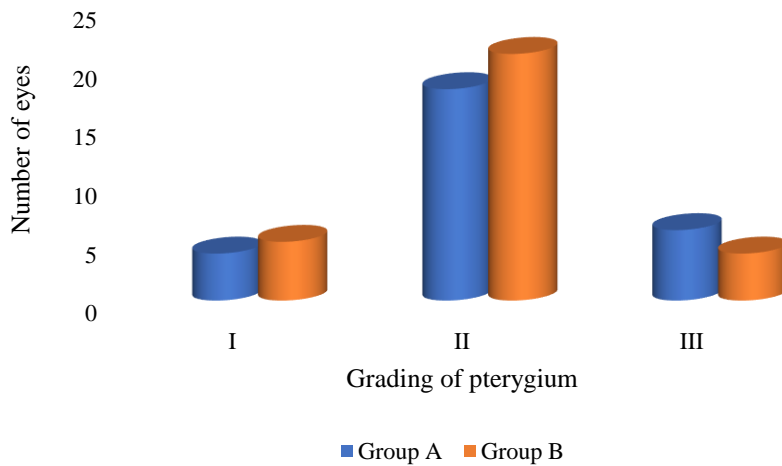
**Fig. 1.** Grading of pterygium

Table 1 shows the grading of pterygium in each group. The above table shows that 4 (14.3%) of the 28 eyes in group A and 5 (16.7%) of the 30 eyes in group B have grade I, 18 (64.3%) of the 28 eyes in group A and 21 out of 30 eyes in group B have grade II, and the remaining 6 eyes in group A and 4 eyes in group B have grade III (Fig. 1).

Table 2. Grading of pterygium and astigmatism

Grading of Pterygium	Astigmatism in diopter (Mean±SD)					
	Group A			Group B		
	Pre-operative	Post-operative	p	Pre-operative	Post-operative	p
I	2.34±2.2	0.96±0.16	0.002	2.45±0.91	0.94±0.31	0.0008

II	2.51±1.4	1.1±0.18	0.0001	2.81±0.55	1.02±0.25	0.0000
III	6.42±0.81	1.2±1.34	0.0000	6.58±1.73	1.19±1.3	0.0000

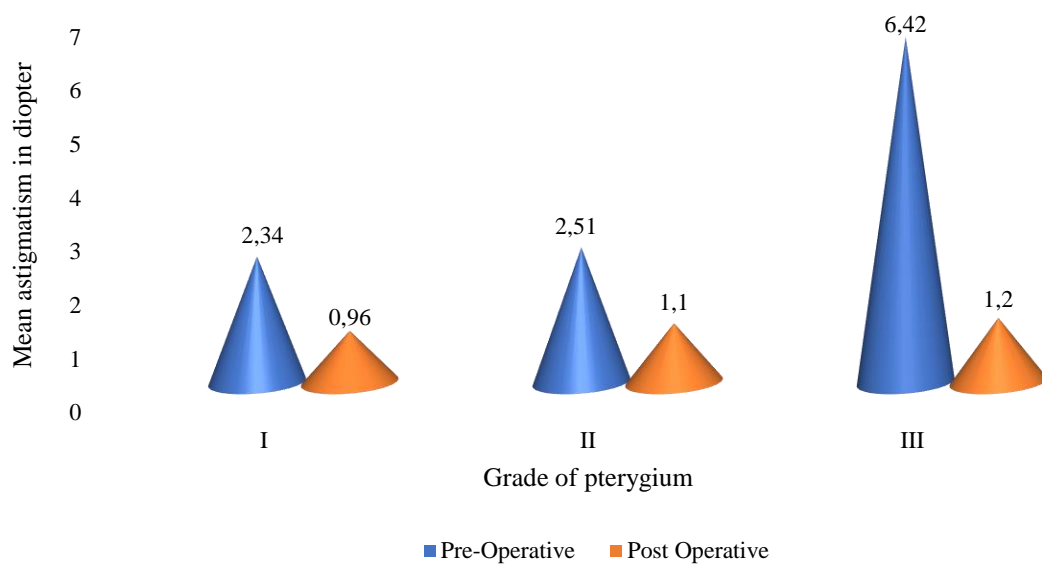


Fig. 2. Grading of pterygium and astigmatism for group A

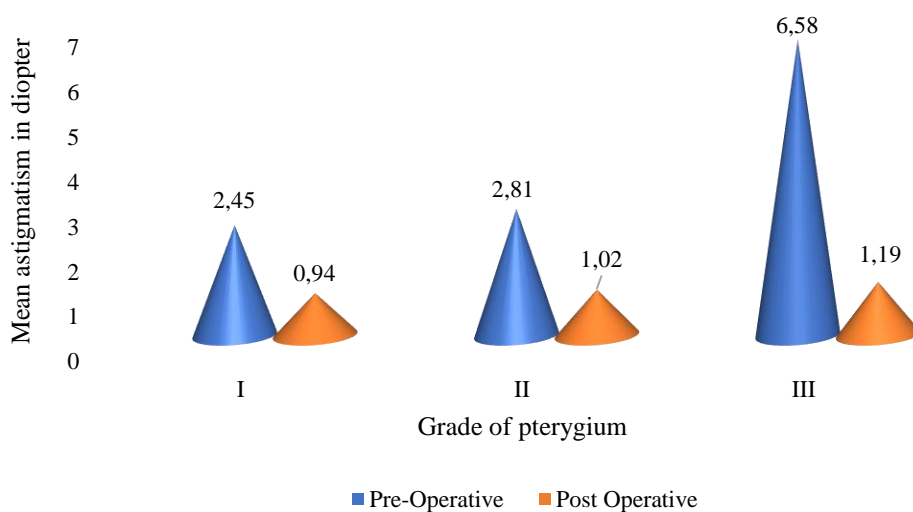


Fig. 3. Grading of pterygium and astigmatism for group B

Table 2 shows the mean astigmatism for each group. The table demonstrates that among patients in group A, the mean astigmatism pre-operatively is 2.34 ± 2.2 diopter (D) and post-operatively 0.96 ± 0.16 D in grade I, 2.51 ± 1.4 D pre-operatively and post-operatively 1.1 ± 0.18 in grade II, and 6.42 ± 0.81 D pre-operatively and post-operatively 1.2 ± 1.34 D in degree III. Preoperative mean astigmatism in group B members is

2.45±0.31 D and post-operatively 0.94±0.31 D in grade I, 2.81±0.55 D pre-operatively and post-operatively 1.02±0.25 D in grade II, and 6.58±1.73 D pre-operatively and post-operatively 1.19±1.3 D in grade III. This suggests that astigmatism rises with pterygium grading in each group ($p < 0.001$). However, for different grades of pterygium, the difference in mean astigmatism in diopters between group A and group B was statistically insignificant ($p > 0.05$) (Fig. 2 and 3).

Table 3. Comparison of values of K1 and K2*

Follow Up	K1					K2					
	Group A		Group B		P-value	Group A		Group B		P	
	Mean	±SD	Mean	±SD		Mean	±SD	Mean	±SD		
Pre-operative	42.55	1.78	43.45	1.89	0.0676	45.23	1.79	44.33	1.83	0.0631	
Post-operative	1 week	43.81	1.63	44.19	1.35	0.3364	46.06	1.82	45.61	1.76	0.3426
	2 weeks	44.09	1.54	44.33	1.41	0.538	46.32	1.84	45.72	1.56	0.1822
	1 month	44.25	1.39	44.21	1.91	0.9281	46.42	1.72	46.78	1.39	0.1236
	3 months	44.51	1.25	44.27	1.12	0.351	46.55	1.66	46.81	1.45	0.5271

* K1 – curvature of cornea in vertical meridian, K2 – curvature of cornea in horizontal meridian

Table 3 shows difference in vertical meridian between preoperative and post-operative values within each group. Between group A and group B, there was no statistically significant difference in the mean values of K1 at various follow-up times ($p > 0.05$). However, in the postoperative follow-up, the values of K1 marginally increased over time.

K1 had pre-operative mean values of 42.55±1.78 for group A and 43.45±1.89 for group B, respectively. For groups A and B, the post-operative at 3 months mean of K1 values were 44.51±1.25 and 44.27±1.12, respectively. This indicates that both group A ($p = 0.0001$) and group B ($p = 0.0475$) experienced statistically significant steepening of the vertical meridian after surgery. It also shows difference in horizontal meridian between preoperative and post-operative values within each group. Between group A and group B, there was no statistically significant difference in the mean values of K2 at various follow-up times ($p > 0.05$). However, in the postoperative follow-up, the mean values of K2 marginally increased over time.

K2 had pre-operative mean values of 45.23±1.79 for group A and 44.33±1.83 for group B, respectively. For groups A and B, the post-operative at 3 months mean of K2 values was 46.55±1.66 and 46.81±1.45, respectively. This indicates that both group A ($p = 0.0051$) and group B ($p = 0.0001$) experienced statistically significant steepening of the horizontal meridian after surgery (Fig. 4).

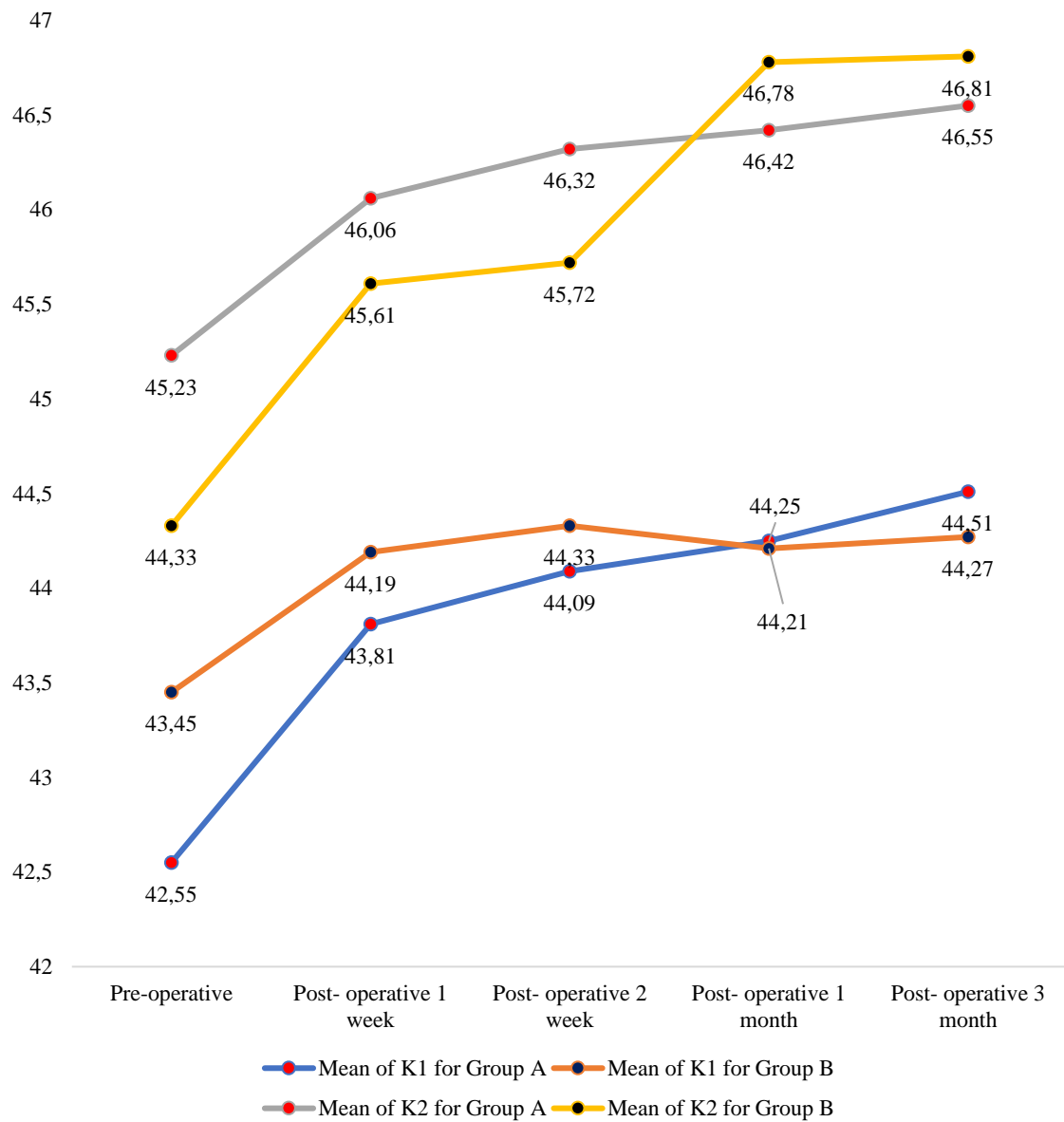


Fig. 4. Comparison of values of K1 and K2

Table 4. Change in mean astigmatism in group A

Follow Up	Number of patients (n=28)	Mean	SD±	p
Pre-operative	28	5	5.8	-
Post-operative 1 week	28	2.1	3.6	0.0249
Post-operative 2 week	26	1.71	1.5	0.0040
Post-operative 1 month	27	1.50	2.1	0.0031
Post-operative 3 month	26	1.18	1.3	0.0009

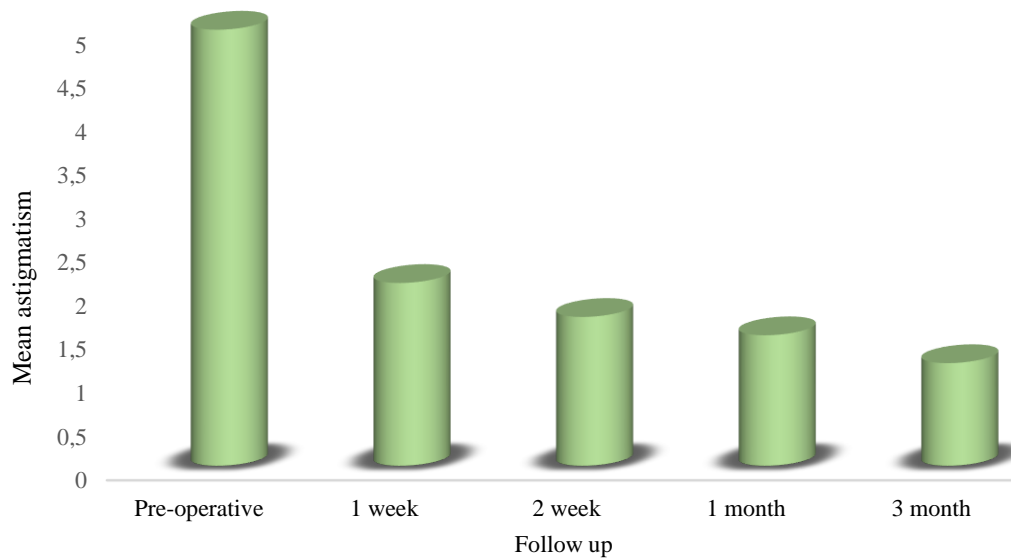


Fig. 5. Change in mean astigmatism in group A

Table 4 shows the change in mean astigmatism in group A after surgery. The Pre operative and post-operative at 3 months mean astigmatism were 5.00 ± 5.8 and 1.18 ± 1.3 , respectively. There was statistically significant reduction in mean astigmatism at each post operative follow up at 1 week ($p=0.0249$), 2 weeks ($p=0.004$), 1 month ($p=0.0031$) and at 3 months ($p=0.0009$). This indicates that group A experienced statistically significant reduction of the mean astigmatism after surgery (Fig. 5).

Table 5. Change in mean astigmatism in group B

Follow Up	Number of patients (n=30)	Mean	SD	p
Pre-operative	30	5.11	5.5	-
Post-operative 1 week	30	2.09	3.2	0.0011
Post-operative 2 week	30	1.77	1.4	0.0021
Post-operative 1 month	27	1.33	2	0.0009
Post-operative 3 month	27	1.12	1.1	0.0003

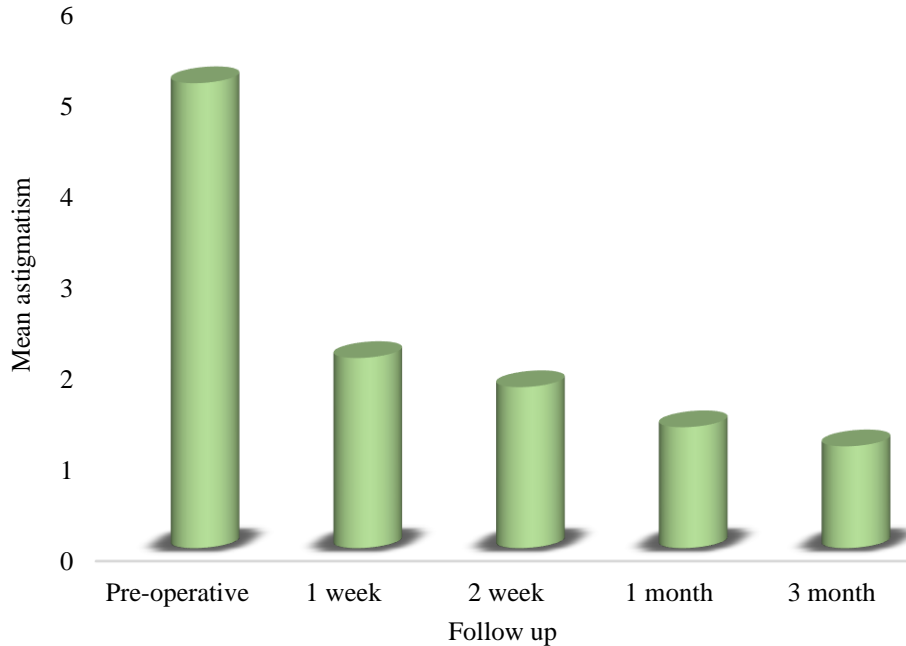


Fig. 6. Change in mean astigmatism in group B

Table 5 shows the change in mean astigmatism in group B after surgery. The Pre operative and post-operative at 3 months mean astigmatism were 5.11 ± 5.5 and 1.12 ± 1.1 , respectively. There was statistically significant reduction in mean astigmatism at each post operative follow up at 1 week ($p=0.0011$), 2 weeks ($p=0.0021$), 1 month ($p=0.0009$) and at 3 months ($p=0.0003$). This indicates that group B experienced statistically significant reduction of the mean astigmatism after surgery (Fig. 6).

Table 6. Comparison of symptoms based on surgery

Symptoms		Pre-operative	Post-operative				Post-operative overall percentage
			1 Week	2 weeks	1 month	3 months	
Pain	Group A	25	20	10	4	1	0.35
	Group B	26	9	1	1	0	0.11
Watering	Group A	24	17	7	2	0	0.27
	Group B	19	6	4	0	0	0.13
FB Sensation	Group A	23	19	6	3	1	0.32
	Group B	22	4	1	1	0	0.069

Table 6 compares symptoms according to the type of surgery. The percentage of eyes that were watering, hurting, or had an FB feeling before surgery was roughly the same in groups A and B. There was a statistically significant difference in the percentage of eyes in groups A and B experiencing pain ($p=0.041$) and FB (0.034), while the difference in the percentage of eyes in groups A and B experiencing watering was insignificant ($p=0.261$). There was no graft displacement in group A while it was noticed in one eye of group B.

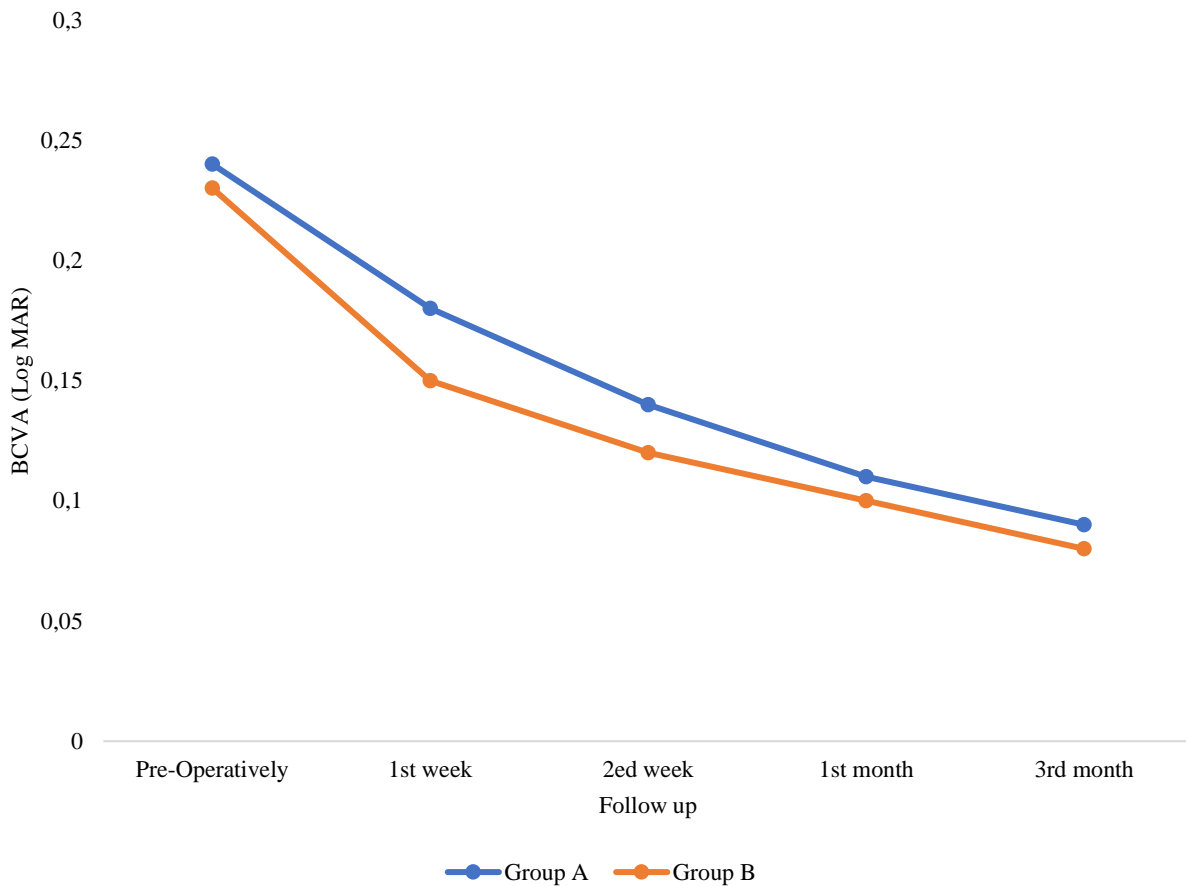


Fig. 7. Comparison of best corrected visual acuity (Log MAR) during follow up

Figure 7 shows that the comparison of best corrected visual acuity (Log MAR) during follow up. In group A mean BCVA (Log MAR) pre-operatively was 0.24 ± 0.2 while it was 0.18 ± 0.1 , 0.14 ± 0.1 , 0.11 ± 0.14 , and 0.09 ± 0.06 at 1st week, 2nd week, 1st month and 3rd month. An ANOVA test of significance revealed a statistically significant improvement in mean visual acuity ($p=0.034$) in group A. In group B mean BCVA (Log MAR) pre-operatively was 0.23 ± 0.18 while it was 0.15 ± 0.14 , 0.12 ± 0.11 , 0.1 ± 0.09 , and 0.08 ± 0.07 at

1st week, 2^{ed} week, 1st month and 3rd month. An ANOVA test of significance revealed a statistically significant improvement in mean visual acuity in group B (p=0.039).

We found that autologous conjunctival autograft has some advantages as compared to sutured conjunctival autograft which are as follows-Availability of patient's own blood, no extra cost, no risk of transmission of blood related diseases, no suture related complications. In comparison to sutured conjunctival autograft there was less watering, pain. Foreign body sensation in autologous conjunctival autograft. Graft stability was more in sutured conjunctival autograft as we found displacement of 1 graft in autologous conjunctival autograft.

Discussion

In our study we found females are more affected than males. Similar findings were found in Asokan et al. and by Tomidokoro et al. in which they stated that pterygium has positive correlation with females.^{8,9} The amount of astigmatism increases with grading of pterygium; the finding has positive correlation with the studies of Payman et al.¹⁰

Table 7. Amount of astigmatism and grading of pterygium

	Group A	Group B	Muhammad Imran Saleem et al. ¹¹	Sulman Jaffar et al. ¹²
Grade 1	2.34±2.2 D	2.45±0.31 D	1.76±0.52 D	1.165±0.849 D
Grade 2	2.51±1.4 D	2.81±0.55 D	2.46±0.74 D	3.46±1.44 D
Grade 3	6.42±0.81 D	6.58±1.73 D	3.57±1.48 D	5.9±0.265 D

The number of astigmatic changes from pre-operative to post operative value is significant in both group A and group B. It has positive correlation with the following studies (Table 7 and 8).

Table 8. Changes in mean astigmatism pre and post operatively

Mean astigmatism±SD	Group A	Group B	Hetal			
			Kumar Yagnik et al. study ¹³	Sejal Maheshwari study ¹⁴	Sejal Maheshwari study ¹⁵	Mohd Yousuf study ¹⁶
Pre-operative	5.0±5.8 D	5.11±5.5	4.23±3.4 D	4.6 ±2.2 D	4.40±3.64 D	4.32± 1.88 D

Post-operative	1.18±1.3 D	1.12±1.1	1.08±1 D	2.2±2.4 D	1.55±1.63 D	2.11±1.96 D
-----------------------	---------------	----------	----------	-----------	-------------	----------------

This verifies the statement that pterygium flattens the cornea and increases the horizontal corneal curvature. There was significant steepening of horizontal and vertical curvature post-operatively in both Group A and group B. Similar findings were seen in the following studies (Table 9).

Table 9. Changes in horizontal and vertical curvature of cornea pre and post operatively

	Group A		Group B		Muhammad Imran Saleem Colleagues study¹¹		Hetal Kumar Yagnik et al. study¹³	
	Horizont al meridian (K1)	Vertical meridian (K2)	Horizont al meridian (K1)	Vertical meridian (K2)	Horizont al meridian (K1)	Vertical meridia n (K2)	Horizont al meridian (K1)	Vertical meridian (K2)
Pre- operati ve	42.55±1. 78 D	45.23±1. 79 D	43.45±1. 89 D	44.33±1. 83 D	43.71±1. 12 D	44.9±1. 41 D	42.15±1. 94 D	45.55±1. 62 D
Post- operati ve	44.51±1. 25 D	46.55±1. 66 D	44.27±1. 12 D	46.81±1. 45 D	44.45±0. 85 D	45.23± 0.78 D	44.41±1. 41 D	46.43±1. 08 D

A statistically significant improvement in mean visual acuity pre-operatively and post-operatively seen in group A and group B was found. Similar findings were seen in Bhandari et al., Zheleva et al., Amoah Kwadwo et al.¹⁷⁻¹⁹ The limitation of this study was its relatively small sample size and short follow up period.

Conclusion

Pterygium surgery decreases the cylindrical error and reverts corneal curvatures to normal thus improving subjective visual acuity. These finding were noted in both sutured CAG and autologous CAG. Astigmatism produced by the pterygium is reduced after surgery. We found that autologous CAG is superior than sutural CAG.

Declarations

Funding

This research received no specific grant from any funding agency in the public, commercial, or not for profit sectors.

Author contributions

Conceptualization, M.J.Y., R.K. and R.M.; Methodology, R.K.; Software, R.K.; Validation, M.J.Y., R.K. and R.M.; Formal Analysis, R.K.; Investigation, R.K.; Resources, T.; Data Curation, R.K.; Writing – Original Draft Preparation, R.K.; Writing – Review & Editing, R.K., M.J.Y. and A.D.; Visualization, R.K.; Supervision, M.J.Y. and R.M.; Project Administration, A.D. and T.; Funding Acquisition, R.K.

Conflicts of interest

No potential conflict of interest was reported by the authors.

Data availability

The datasets generated during and/or analysed during the current study are available from the corresponding author on reasonable request.

Ethics approval

Written permissions were obtained from the Ethical Committee of Shri Shankaracharya Institute of Medical Sciences (SSIMS/EC/2022/21). The participants were informed about the purpose, method, and plan of the study by the researchers, and their informed consent were obtained.

References

1. Ang LP, Chua JL, Tan DT. Current concepts and techniques in pterygium treatment. *Curr Opin Ophthalmol.* 2007;18(4):308-313. doi: 10.1097/icu.0b013e3281a7ecbb
2. Brightbill FS. *Corneal Surgery: Theory, Technique and Tissue.* Mosby: Mosby Elsevier; 2009.
3. Rokohl AC, Heindl LM, Cursiefen C. Pterygium: pathogenesis, diagnosis and treatment. *Ophthalmologe.* 2021;118(7):749-763. doi: 10.1007/s00347-021-01366-9
4. Lindsay RG, Sullivan L. Pterygium-induced corneal astigmatism. *Clin Exp Optom.* 2001;84(4):200-203. doi: 10.1111/j.1444-0938.2001.tb05026.x
5. Tan DTH. Effect of Pterygium Morphology on Pterygium Recurrence in a Controlled Trial Comparing Conjunctival Autografting With Bare Sclera Excision. *Arch Ophthalmol.* 1997;115(10):1235. doi: 10.1001/archopht.1997.01100160405001
6. Kirti Nath Jha. ResearchGate. https://www.researchgate.net/publication/275970613_Pterygium_Excision_and_Conjunctival-Limbal_Autograft_Transplantation_A_Simplified_Technique. Accessed September 5, 2023.

7. Shusko A, Schechter BA, Hovanesian JA. Pterygium Surgery Utilizing Limbal Conjunctival Autograft and Subconjunctival Amniotic Membrane Graft in High-Risk Populations. *Clin Ophthalmol.* 2020;14:2087-2090. doi: 10.2147/OPHTH.S243584
8. Asokan R, Venkatasubbu RS, Velumuri L, Lingam V, George R. Prevalence and associated factors for pterygium and pinguecula in a South Indian population. *Ophthalmic Physiol Opt.* 2012;32(1):39-44. doi: 10.1111/j.1475-1313.2011.00882.x
9. Tomidokoro A. Effects of pterygium on corneal spherical power and astigmatism. *Ophthalmology.* 2000;107(8):1568-1571. doi: 10.1016/s0161-6420(00)00219-0
10. Mohammad-Salih PA-K, Sharif AFMD. Analysis of Pterygium Size and Induced Corneal Astigmatism. *Cornea.* 2008;27(4):434-438. doi: 10.1097/ico.0b013e3181656448
11. Saleem MI, Saleem Channar M, Saleem MF. Effects of Pterygium Excision on Corneal Curvatures. *Pak J Med Sci.* 2011;27(2):325-328.
12. Jaffar S, Dukht U, Rizvi F. Impact of Pterygium Size on Corneal Topography. *RMJ.* 2009;34(2):145-147.
13. Yagnik H K, Billore O P, Das S, et al. Corneal Topographical Changes after Pterygium Excision Surgery: A Reason to Smile. *All India Ophthalmic Conference Proceedings.* 2008:27-29.
14. Khanna RC, Honavar SG, Metla AL, Bhattacharya A, Maulik PK. Psychological impact of COVID-19 on ophthalmologists-in-training and practising ophthalmologists in India. *Indian J Ophthalmol.* 2020;68(6):994-998. doi: 10.4103/ijo.IJO_1458_20
15. Maheshwari S. Pterygium-induced corneal refractive changes. *Indian J Ophthalmol.* 2007;55(5):383-386. doi: 10.4103/0301-4738.33829
16. Yousuf M. ResearchGate. https://www.researchgate.net/publication/283137779_Role_of_ptyerygium_excision_in_ptyerygium_induced_astigmatism. Accessed September 25, 2023.
17. Bhandari V, Rao CL, Ganesh S, Brar S. Visual outcome and efficacy of conjunctival autograft, harvested from the body of pterygium in pterygium excision. *Clin Ophthalmol.* 2015;9:2285-2290. doi: 10.2147/opth.s93580
18. Zheleva V, Voynov L. Comparative study of astigmatic changes following pterygium excision with conjunctival autograft transplantation. *Biotechnology & Biotechnological Equipment.* 2018;32(2):433-436. doi: 10.1080/13102818.2017.1423516
19. Amoah K, Lartey SY, Mohammed AK, Ahmed AS, Arthur KAN, Kyei EN. Changes in Astigmatism and Visual Acuity after Pterygium Excision in the Ashanti Region of Ghana. *Annals of African Surgery.* 2022;19(2):86-93. doi: 10.4314/aas.v19i2.5