



CASUISTIC PAPER

Dominik Godlewski^{1(ABCDEF)}, Patryk Pszczółkowski^{1(ABCD)}, Tadeusz Fedus^{1(ABCD)},
David Aebisher^{2(EF)}

Bladder leiomyoma: diagnostics, laparoscopy, and treatment

¹ Clinical Department of Urology and Oncological Urology Clinical Provincial Hospital No.1, Rzeszów, Poland

² Department of Photomedicine and Physical Chemistry, Medical College of Rzeszów University, Rzeszów, Poland

ABSTRACT

Introduction. Leiomyosarcoma is the most common benign tumor of the bladder. However, it is only a small percentage of all proliferative changes of this organ.

Aim. Presentation based on two clinical cases of diagnostics and surgical treatment from laparoscopic access of bladder leiomyoma.

Description of the cases.

Case 1. The work contains a diagnosis based on transvaginal ultrasound (TVUS), cystoscopy and computed tomography (CT), as well as partial laparoscopic bladder resection of leiomyoma in young women.

Case 2. The case of young women with the histopathological result confirmed bladder leiomyoma.

Conclusions. Leiomyoma is a rare bladder cancer. Laparoscopic bladder resection is a safe method that leads to healing.

Keywords. bladder leiomyoma, endometriosis, laparoscopic surgery

Introduction

Leiomyoma is a benign tumor of mesenchymal origin. Although the bladder is the most common localization of leiomyosarcoma in the urinary system and is the most common benign lesion of this organ (35%), leiomyoma is only 0.5% of all bladder tumors.¹⁻⁴ The disease occurs three times more common in women than men² with a peak incidence between the third and eighth decade of life. The average age of diagnosis is 45 years.⁵⁻⁹ Symptoms of leiomyosarcoma are non-specific and depend on the size and location of the tumor. The most common are: impaired urination (49%), dysuria (38%), lumbar pain (13%) and hematuria (11%). In 19%, the

change can be completely asymptomatic and constitutes an accidental diagnosis. In 57% of women, these tumors are palpable in a two-handed study.^{3,7,8,10}

Diagnosis is based on physical examination, imaging techniques and cystoscopy. Helpful in the diagnosis of imaging include transabdominal or transvaginal ultrasound, which is usually the first diagnostic step, as well as computed tomography and magnetic resonance imaging.

In the differential diagnosis, the presence of leiomyosarcoma or other bladder tumors and urinary endometriosis should be taken into account.

Corresponding author: Dominik Godlewski, E-mail: dogod@o2.pl

Participation of co-authors: A – Author of the concept and objectives of paper; B – collection of data; C – implementation of research; D – elaborate, analysis and interpretation of data; E – statistical analysis; F – preparation of a manuscript; G – working out the literature; H – obtaining funds

Received: 3.06.2020 | Accepted: 8.08.2020

Publication date: September 2020

Aim

Presentation based on two clinical cases of diagnostics and surgical treatment from laparoscopic access of bladder leiomyoma.

Description of the cases

Case 1.

In a 30-year-old woman preparing for pregnancy, during a follow-up visit to the gynecologist, an asymptomatic tumor of the anterior bladder wall was found on ultrasound. In an interview, delivery by caesarean section 2 years ago. The patient did not report dysuria or cyclic hematuria, however, the change in the bladder described in ultrasound could suggest endometriosis due to the patient's gynecological history.

The patient is in good general condition, without any complaints or perceptible pathologies in the physical examination. Blood and urine tests without deviation from the norm. Computed tomography (CT) scan with contrast of the abdominal cavity and pelvis was performed as part of diagnostic imaging. It showed the presence in the anterior wall of the bladder of a tumor with smooth outlines and dimensions of 14 x 28 x 27 mm, undergoing slight contrast enhancement (up to 22 JH), having densities similar to the uterine endometrium, which would suggest a focus of endometriosis (Figure 1).

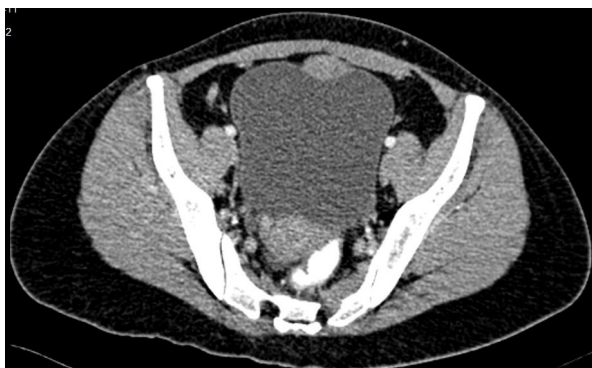

Fig. 1. Leiomyoma of the anterior wall of the bladder

Peritoneal implants were not disclosed, and no pathological features were found in the other abdominal, retroperitoneal and pelvic organs. Lymph nodes of the retroperitoneal space and the pelvis minor enlarged.

On the basis of the above tests, it was decided to schedule the patient's admission to the Urology Clinic of the Provincial Specialist Hospital in Rzeszów for cystoscopy and possible qualification for surgical treatment. In endoscopic examination under general anesthesia, prior to the planned surgery, only the anterior wall impression was suggested suggesting its external modeling or the existence of an intramural lesion, which was confirmed by the CT image. There are no

lesions that could be subjected to transurethral resection. Both sides were equipped with DJ catheters for easier intraoperative identification of ureters and decided to laparoscopic tumor resection. A Foley 16Fr catheter was left in the bladder. Patient lying in Trendelenburg position, deflected to 15°, after peritoneal optical trocar (10mm) was introduced by minilaparotomy in the navel, peritoneal pneumothorax was created. Two more working trocars (10 mm and 5 mm) were placed on both sides in the projection of the lateral edges of the straight abdominal muscles, two fingers below the navel. Adhesions were found in the lower part of the peritoneal cavity after caesarean section, which were released revealing the anterior wall of the bladder. After filling it with physiological saline, the tumor was identified. The lesion was excised with a healthy tissue margin (Figure 2).

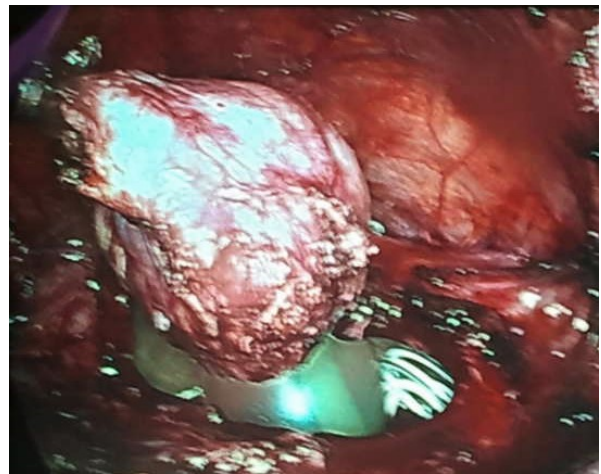


Fig. 2. Leiomyoma of the anterior wall of the bladder

The anterior wall of the bladder was sutured with a laparoscopic 2-layer continuous 3-0 suture.

Bladder tightness was checked, Redon drain was left. Intraoperative blood loss was trace, not significant. Postoperative course without complications. The drain was removed on the second day after surgery. The patient was discharged from the clinic on the fourth postoperative day with the Foley catheter and DJ stents left behind.

As a result of histopathological examination, a 1.5x0.5x2.5cm leiomyoma-type bladder lesion was described - a tumor excised with a healthy tissue margin. Immunohistochemical tests: DES (+), SMA (+), S100 (+/-), CD-34 (-), CD-117 (-), VIM (-). The patient was admitted again after two weeks. Cystography was performed giving 170 ml of contrast. Smooth-walled bladder, no contracting defects, no leakage of contrast.

The Foley catheter and ureteral catheters were removed. No bladder retention after voiding.

The patient quickly returned to full activity, and two months after the surgery resumed sports training.

Case 2.

Another patient, aged 30, was referred by a urologist because of computed tomography of a 31x31x28 mm bladder tumor adjacent to the vaginal wall and located near the left ureteral outlet, (Figure 3).

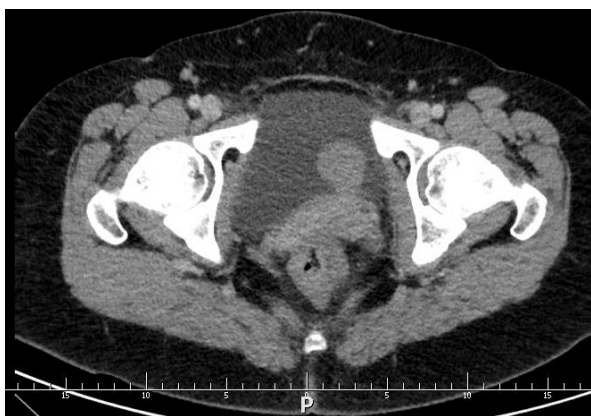

Fig. 3. Leiomyoma of the left bladder wall - CT II-phase image- 31x31x28 mm bladder tumor

The initial diagnosis was based on an ultrasound examination made for recurrent haematuria. The patient did not report any other ailments. The renal calf-pelvic system without stasis in imaging (USG, computed tomography).

During hospitalization, the patient was consulted gynecologically - a tumor palpable was found through the left vaginal vault, and TVUS revealed the above-mentioned change in the bladder wall. In cystoscopic examination, visible mass penetrating into the lumen of the bladder covered with unchanged mucosa over the left ureteral opening (Figure 4).

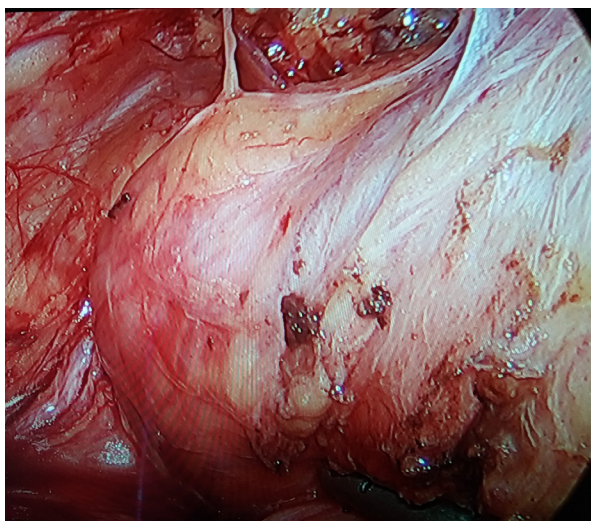


Fig. 4. Leiomyoma of the left bladder wall - laparoscopic image. 31x31x28 mm bladder tumor

It was decided to have surgery - partial laparoscopic resection of the bladder. The left ureter was stented under anesthesia to facilitate its intraoperative identification. Then four trocars were introduced. The tumor was reached laterally from the lateral umbilical fold. Using the Thunderbeat® device, a lesion was removed with an unchanged tissue margin (Figure 5).

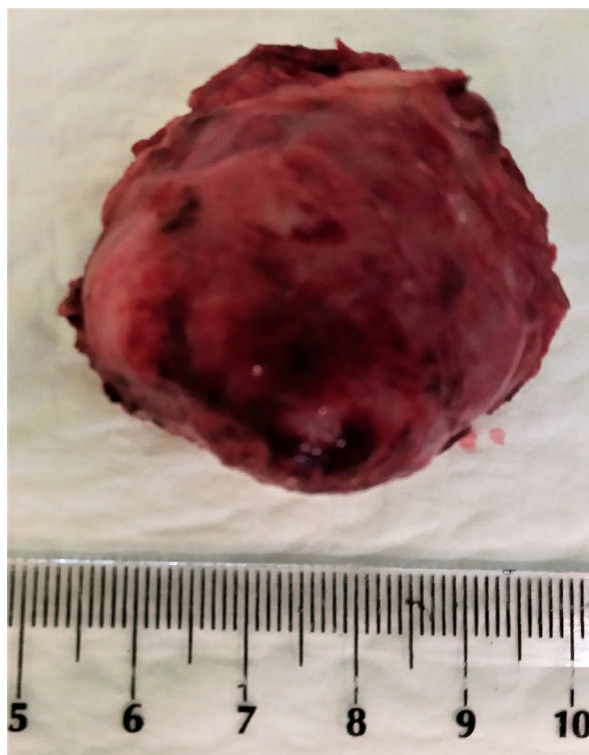


Fig. 5. Leiomyoma of the left bladder wall - condition after removal of the tumor

The bladder was sutured with a continuous suture, its tightness was checked. Postoperative course without complications, drainage removed on the third day after surgery. Foley's catheter was left and removed along with the DJ catheter 10 days after surgery. No adverse effects were found.

The histopathological result confirmed bladder leiomyoma. The picture corresponded to a poor cell, spindle cell tumor in the muscularis of the bladder wall. Mitosis and necrosis were not found. In immunohistochemistry, strongly actin and SMA positive cells, few estrogen positive cells, CD 117 and S 100, negative for CK Pan, Ki67 about 1%. Urothelial epithelium without dysplasia. A tumor cut out entirely with a margin.

Discussion

63% of the bladder leiomyosarcoma occurs submucosa, and the mucosa covering it is unchanged in the cystoscopic image. 11-30% of lesions are located in the subserum and 7-17% are intramural.^{7,10,11} The etiology of the disease remains unclear. The accepted hypotheses are

a chromosomal defect, hormonal disorders (which may explain the more frequent occurrence in women), recurrent detrusor infections, vasculitis, or dysontogenesis.^{12,13} Available data are quite scarce. In the available English literature since 1953, only about 250 cases of the described disease were reported.¹⁴ Submucosal tumors have the appearance of peduncular polyps, whereas intramural masses have the character of a capped lesion surrounded by a bladder wall.¹⁴

In diagnostics, per vaginam and per rectum tests are used, as well as various imaging tests - transabdominal or transvaginal ultrasound, computed tomography or magnetic resonance imaging, and cystoscopy.^{1,3,8,11,14,17-22} Ultrasound examination reveals homogeneous echogenicity of the tumor with scanty vascularization in Doppler examination. CT allows differentiation between the solid and cystic nature of the lesions and accurately assesses the attitude towards surrounding tissues, showing weak amplification to 25 - 50 Hounsfield units, which confirms poor vascularization of the lesions.^{11,14} MRI has greater specificity for mesenchymal components, allows to assess the relation to neighboring structures. This image shows homogeneously strengthening tumors, others with cystic degeneration with a hyperintensive signal in T2-dependent images. It is worth emphasizing that none of the imaging tests exclude the malignant nature of the lesion, so it should be obligatory to obtain material for histopathological examination, whether by biopsy during cystoscopy or by complete removal of the tumor. Percutaneous, suprapubic biopsy in a pregnant patient has also been described.^{14,22} In the histopathological picture, degenerative changes, hyalinization, necrosis, fat metaplasia and mucilage can be observed.⁵ In the differential diagnosis, first of all, the leiomyosarcoma change should be taken into account, since in the form of high-grade mortality accounts for up to 50% with an observation period of 22-47 months.^{5,6} In addition, differentiation applies to other bladder tumors, its diverticula and cysts, and endometriosis. The method of treatment is determined by the location of the tumor. In submucosal localization, transurethral resection (TURBT) is possible, while in intramural and subserous position resection by open surgery, laparoscopic, or be robotic.^{3,5-8,10,11,14-19} In the case of complete leiomyoma excision, no tumor recurrence or malignancy are observed.^{2,3,5,6,8} Barayan and Nassir report the need for re-TURBT in 18% of patients due to incomplete transurethral resection and the lack of such necessity after open surgery.³ Considering the excellent imaging that allows close and enlarged assessment of resection borders, as well as easy access to lesions located both on the anterior wall, the top of the bladder and on its back wall, reduction of postoperative pain and quick recovery of laparoscopic operations constitute an effective and minimally invasive method of treating this type of tumor.

The risk of complications in the form of damage to surrounding structures, including abdominal organs (transperitoneal access) is largely dependent on the skill and experience of the operator.

Conclusions

Surgical treatment of bladder leiomyoma is the method of choice because it allows complete removal of the lesion, providing material for histopathological examination, which is important due to the differentiation of pathological mass with leiomyosarcoma and other bladder tumors or endometriosis. Excellent treatment effectiveness is observed, i.e. a very low recurrence rate, resolution of symptoms, as well as very good long-term prognosis.

Laparoscopic surgery for intramural and subserous lesions is a minimally invasive, precise method of treatment (excellent insight into the surgical field), allowing the patient to quickly return to daily functioning - as in the described case, also to actively play sports. In centers with experience in laparoscopic techniques, previous pelvic surgery, as in the case of the Caesarean section, is not a contraindication to choosing this method of treatment.

References

1. Roy MK, Joarder RH, Suruzzaman M, et al. Leiomyoma of the urinary bladder. *Mymensingh Med J.* 2005;14(2):209-211.
2. Dogra PN, Jadeja NA, Gupta NP. Leiomyoma of the urinary bladder: a report of 3 cases. *Indian J Urol.* 1993;9(1):17-19.
3. Ghassan A. Barayan and Anmar M. Nassir: Cystoscopic enucleation of bladder leiomyoma. *Urol Ann.* 2012;4(1):38-40.
4. Mendes JE, Ferreira AV, Coelho SA, Gil C. Bladder leiomyoma. *Urol Ann* 2017;9:275-277.
5. Lee TK, Miyamoto H, Osunkoya AO, et al. Smooth muscle neoplasms of the urinary bladder: a clinicopathologic study of 51 cases. *Am J Surg Pathol.* 2010;34(4):502-509.
6. Martin SA, Sears DL, Sebo TJ, et al. Smooth muscle neoplasms of the urinary bladder: a clinicopathologic comparison of leiomyoma and leiomyosarcoma. *Am J Surg Pathol.* 2002;26(3):292-300.
7. Lin Y, I-Sheng Hwang T. Leiomyoma of Urinary Bladder: A Case Report and Literature Review. *J Urol ROC.* 2001;12:96-98.
8. Matsushima M, Asakura H, Sakamoto H. Leiomyoma of the bladder presenting as acute urinary retention in a female patient: urodynamic analysis of lower urinary tract symptom; a case report. *BMC Urology.* 2010;10:13.
9. Haddad RG, Murshidi MM, Abu Shahin N, Murshidi MM. Leiomyoma of Urinary Bladder Presenting with Febrile Urinary Tract Infection: A Case Report. *Intern J Surg Case Rep.* 2016;27:180-182.

10. Castillo O, Foneron A, Vitagliano G, et al. Bladder leiomyoma: case report. *Arch Esp Urol*. 2008;61(1):87-91.
11. Yucel A, Haktanir A, Albayrak R, et al. *Intramural leiomyoma of the urinary bladder: Diagnostic value of CT vs US. Tip Arastirmalari Dergisi*. 2004;2(3):37-40.
12. Cornella JL, Larson TR, Lee RA, Magrina JF, Kammerer-Doak D. Leiomyoma of the female urethra and bladder: report of twenty-three patients and review of the literature. *Am J Obstet Gynecol*. 1997;176:1278-1285.
13. Goluboff ET, O'Toole K, Sawczuk IS. Leiomyoma of bladder: report of case and review of literature. *Urology*. 1994;43:238-241.
14. Nazih Khater, Ghazi Sakr: Bladder leiomyoma: Presentation, evaluation and treatment. *Arab J Urol*. 2013;11(1):54-61.
15. Laato M, Ekfors T, Alanen A, et al. Leiomyoma of the urinary bladder. *Ann. Chir Gynaecol Suppl*. 2001;215:55-57.
16. Chen CC, Huang CH, Chu CH, et al. Leiomyoma of the urinary bladder: a case report. *Kaohsiung J Med Sci*. 2003;19(3):141-145.
17. Patrozos K, Westphal J, Trawinski J, et al. Total laparoscopic excision of a leiomyoma of the urinary bladder – a case report. *Aktuelle Urol*. 2005;36(1):58-60.
18. Jeschke K, Wakonig J, Winzely M, et al. *Laparoscopic partial cystectomy for leiomyoma of the bladder wall. J Urol*. 2002;168:2115.
19. Thiel DD, Williams BF, Krishna M, et al. Robot-assisted laparoscopic excision of bladder wall leiomyoma. *J Endourol*. 2009;23(4):579-582.
20. Saunders SE, Conjeski JM, Zaslau S, et al. Leiomyoma of the urinary bladder presenting as urinary retention in the female. *Can J Urol*. 2009;16(4):4762-4764.
21. Fernández Fernández A, Mayayo Dehesa T. Leiomyoma of the urinary bladder floor: diagnosis by transvaginal ultrasound. *Urol Int*. 1992;48(1):99-101.
22. Mizuno K, Sasaki S, Tozawa K, et al. Leiomyoma of the urinary bladder during pregnancy. *Int J Urol*. 2003;10(7):407-409.
23. Wong FK, Wong YFM, Ma, CY Lui KF. Urinary Bladder Leiomyoma. *J Coll Radiol* 2002;5:193-196.