

This is a provisional PDF only. Copyedited and fully formatted version will be made available soon.

Authors: Bogdan O. Shcheglov, Ivan V. Reva, Dmitry P. Puga, Irina P. Koval, Svetlana N. Shcheglova, Marina B. Khamoshina, Viktor V. Usov, Kirill V. Stegnyy, Galina V. Reva

Article type: Original Article

Received: 21 April 2024

Accepted: 6 September 2024

Published online: 24 October 2024

eISSN: 2544-1361

Eur J Clin Exp Med

doi: 10.15584/ejcem.2025.1.10

This is a PDF file of an unedited manuscript that has been accepted for publication. As a service to our customers we are providing this early version of the manuscript. The manuscript will undergo copyediting and typesetting. Please note that during the production process errors may be discovered which could affect the content, and all legal disclaimers that apply to the journal pertain.

Analysis of cervical mucosal epithelium proliferation during the postmenopausal period

Bogdan O. Shcheglov ¹, Ivan V. Reva ¹, Dmitry P. Puga ¹, Irina P. Koval ¹, Svetlana N. Shcheglova ²,
Marina B. Khamoshina ³, Viktor V. Usov ¹, Kirill V. Stegnyy ¹, Galina V. Reva ¹

¹ Far Eastern Federal University, Vladivostok, Russia

² North-Eastern State University, Magadan, Russia

³ Peoples' Friendship University of Russia, Moscow, Russia

Corresponding author: Bogdan O. Shcheglov, e-mail: b.shcheglov@mail.ru

ORCID

BOS: <https://orcid.org/0000-0002-2262-1831>

IVR: <https://orcid.org/0000-0002-3727-393X>

DPP: <https://orcid.org/0000-0002-4322-0359>

IPK: <https://orcid.org/0000-0001-8648-3725>

SNS: <https://orcid.org/0000-0001-5898-9120>

MBK: <https://orcid.org/0000-0003-1940-4534>

VVU: <https://orcid.org/0000-0002-1182-7551>

KVS: <https://orcid.org/0000-0003-0472-9504>

GVR: <https://orcid.org/0000-0001-6502-4271>

ABSTRACT

Introduction and aim. This study explores the proliferative growth of cervical mucosal epithelial cells during the postmenopausal period, offering new insights on age-related changes in cervical tissues, a topic previously under-examined in postmenopausal health research. By employing histologic analysis, immunostaining techniques, and Ki-67 mitotic index assessment, this research provides novel data on the alterations in cervical epithelial cells during and after menopause. The findings enhance our understanding of the biological processes affecting cervical health in the postmenopausal phase, which is increasingly significant as the global population ages and emphasizes the need for tailored healthcare approaches. The primary goal was to investigate the proliferative growth of cervical mucosal epithelial cells in postmenopausal women by assessment of Ki-67 gene activity in progesterone-positive cells in normal and pathological postmenopausal periods (PMPs) in the presence or absence of autonomic symptoms, manifested by mood instability, headaches and dizziness.

Material and methods. This research involved analyzing tissue samples from 149 postmenopausal women with suspicion of malignancy using histologic and immunostaining methods to evaluate epithelial cell proliferation markers, with the Ki-67 mitotic index as a key measure. The average activity of the Ki-67 gene was evaluated using the global scoring method, with Ki-67 percentages below 2.5% considered low. Statistical analysis included both parametric and non-parametric methods, specifically Student's t and Wilcoxon's tests.

Results. The study found a reduction in the proliferative activity of cervical mucosal epithelial cells during the normal postmenopausal period, indicated by a significant decrease in Ki-67 expression in the exocervical zone and during the first year in the transformation zone and the endocervix ($p < 0.01$).

Conclusion. Understanding the proliferative growth of cervical mucosal epithelial cells during the postmenopausal period helps to understand the dynamics of age-related cervical tissue. These results can lead to better prevention and monitoring strategies for cervical health in postmenopausal women.

Keywords. Cervix, Ki-67, postmenopausal period, proliferative growth

Introduction

According to the global scientific literature, it is known that the outside of the cervix is covered with a pink-colored multilayer squamous epithelium.¹⁻³ Four main layers of keratinocytes have been identified in the multilayer epithelium:

- the first layer – basal cells (characterized by large nuclei and high nuclear-cytoplasmic ratios),
- the second layer – parabasal cells,
- the third layer – intermediate cells,
- the fourth layer – superficial cells with low nuclear-cytoplasmic ratios, containing glycogen.

At the external cervix, the squamous epithelium, which consists of multiple layers, interfaces with cylindrical epithelial cells.^{4,5} Occasionally, cylindrical epithelium can extend to the cervix's outer surface and around the external os, a phenomenon known as ectopia. This is a common occurrence in newborn girls, where the cylindrical epithelium gradually transitions into multilayered squamous epithelium as they age. This transformation is facilitated by reserve cells located between cylindrical epithelial cells, which give rise to patches of multilayered squamous epithelium.^{6,7}

Ectopia may also result from the body's response to hormonal contraceptives or pregnancy and can occur due to hormonal treatments during the postmenopausal period to extend menopause and prevent rapid involution of the genitourinary organs.^{8,9} In women of reproductive age, the boundary between the squamous and cylindrical epithelium is typically aligned with the external os, while in younger women, it is located on the endocervix and in older women, it is found within the cervical canal. This boundary, known as the transformation zone, is crucial and warrants meticulous examination by specialists.¹⁰⁻¹² The cervical epithelium is a complex multilayered system that interacts intricately both internally and with the adjoining

cylindrical epithelium.

Menopause significantly impacts various physiological processes, including the structure and function of cervical tissues. The postmenopausal period is characterized by a decline in estrogen levels, leading to thinning of the cervical epithelium and a reduction in its regenerative capacity. This hormonal change contributes to a decreased proliferative activity of cervical mucosal (CM) epithelial cells, as indicated by lower Ki-67 expression, and a diminished ability to respond to environmental and physiological challenges. Furthermore, menopause is associated with changes in the microenvironment of the cervix, such as altered immune responses and increased susceptibility to infections and neoplastic transformations.¹³ The impact of menopause on cervical health is further complicated by infections by human papillomavirus (HPV). HPV, particularly high-risk strains like HPV-16 and HPV-18, disrupt normal cellular processes by inactivating tumor suppressor proteins p53 and Rb via its oncoproteins E6 and E7. This leads to uncontrolled cell proliferation, impaired apoptosis, and genomic instability. HPV-induced changes can transform normal endocervical epithelium into precancerous lesions, increasing the risk of cervical cancer.^{14,15} Therefore, understanding the combined effects of menopause and HPV infection is crucial for developing tailored medical approaches to manage cervical health in postmenopausal women.

The cervix has three distinct sections characterized by unique morphological features and varying immunological activities. The physiological regeneration of these different epithelial layers involves cambium-like cells and follows diverse signaling pathways for differentiation and specialization. This process necessitates an understanding of not just cellular plasticity but also the patterns of neurohormone systems, known as keilons.¹⁶ The intermediate area, known as the transformation zone, is a critical site for microbial contamination and the localization of cells prone to malignancy.¹⁷ Research has yet to fully explore the phenotypes of innate and adaptive immune cells and their interactions under conditions of papillomavirus infection. Studies by the authors have revealed that the quantitative and qualitative characteristics of the differon system, including local mucosal immunity, differ significantly from those in more proximal regions.

Aim

The research aim is to investigate the proliferative growth of cervical mucosal epitheliocytes by assessment of Ki-67 gene activity in progesterone-positive cells during normal and pathological postmenopausal periods (PMPs).

Material and methods

The main aim of this research was to explore the proliferative growth of cervical mucosal epithelial cells in patients from the Primorsky Region across various age groups. The study involved analyzing 149 cervical mucosa biopsy specimens prepared at the Medical complex of Far Eastern University that were collected

from patients with clinical indications for malignancy in accordance with the Declaration of Helsinki (2000, 2013) and approved by the Local Ethics Committee of Far Eastern Federal University, Vladivostok (protocol No. 6 dated April 19, 2023).

The study compared the clinical material of women (in equal proportions, 74 and 75, respectively) with the normal and pathological course of the postmenopausal period (depending on the presence or absence of persistent symptoms in the form of vegetative-vascular manifestations with emotional instability, headaches and dizziness). Observed samples were obtained from different patients for 5 years. During the first year of study biopsies of 25 patients were analyzed, the second year 30 patient samples were analyzed, the third year 42 patient samples were analyzed, the fourth year 33 patient samples were analyzed, and the 5th year 29 patient samples were analyzed. Patients did not have high HPV activity, surgical interventions, or hormonal medications in the past 10 years before visiting a gynecologist. The normal postmenopausal period occurred in women without signs of cellular atypia and malignancy (those women in whom immunohistochemistry (IHC) did not confirm the presence of factors predisposing to tumor growth). In the pathological postmenopausal period, signs of cellular atypia with high Ki-67 activity were found.

Progesterone-positive cells were identified in routine IHC diagnosis. As a marker, a monoclonal antibody clone of the progesterone receptor (PgR 636), specifically targets the progesterone receptor (PR), was applied. This antibody binds to the PR protein in formalin-fixed paraffin-embedded tissue sections, allowing the detection of PR-expressing cells. Following primary antibody binding, a secondary antibody conjugated with an enzyme or fluorescent marker was applied, enabling visualization under a microscope, typically as a brown chromogenic signal.

General morphological characteristics were identified using hematoxylin and eosin staining, while proliferative activity in the epithelial lamina was assessed by the Ki-67 marker, counting mitoses per 100 cells. Progesterone-positive cells were quantified by IHC assessment of level protein expression over a 4 mm² area, with ≥ 13 positive cells distinguishing normal course from pathological course of the postmenopausal period. Average Ki-67 gene activity was evaluated using the global scoring method, with Ki-67 percentages below 2,5% considered low. Statistical analysis employed both parametric and non-parametric methods, including Student's and Wilcoxon's tests, facilitated by standard software packages like LYSYS II ("Becton Dickinson Immunocytometry system"). Visual documentation was captured using a digital camera with DP×25 software.

Results

Analysis of proliferative activity at different stages of a the postmenopausal period showed differences in various sections of the cervical mucosa (Figs. 1 and 2).

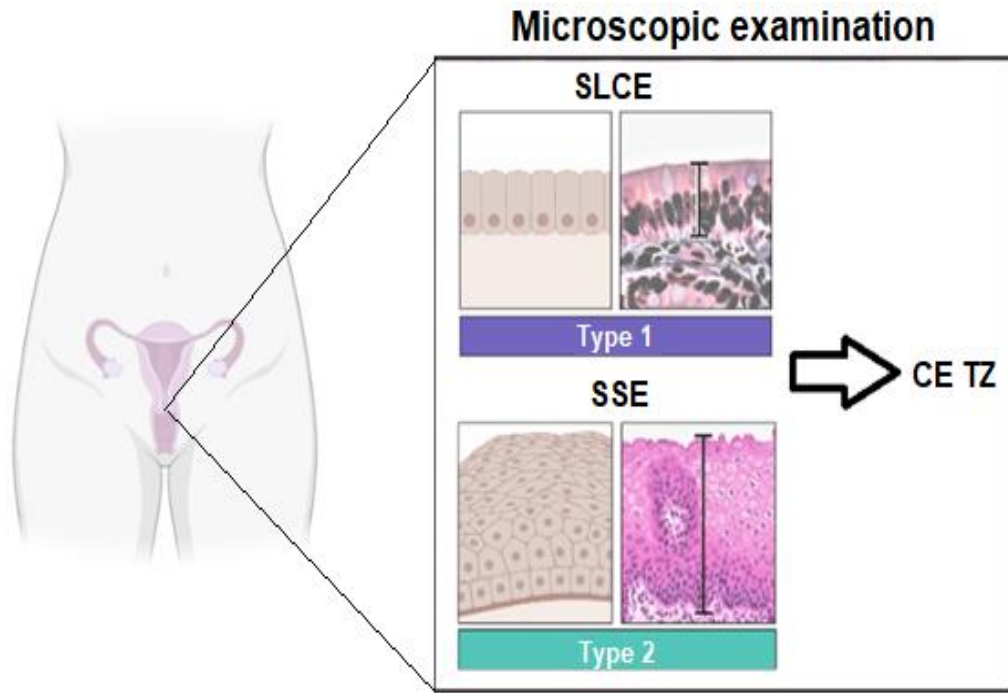


Fig. 1. Scheme of the cervical epithelium, SSE stratified squamous epithelium of the exocervix, CE TZ columnar epithelium of the transformation zone, SLCE single-layered cylindrical epithelium of the endocervix

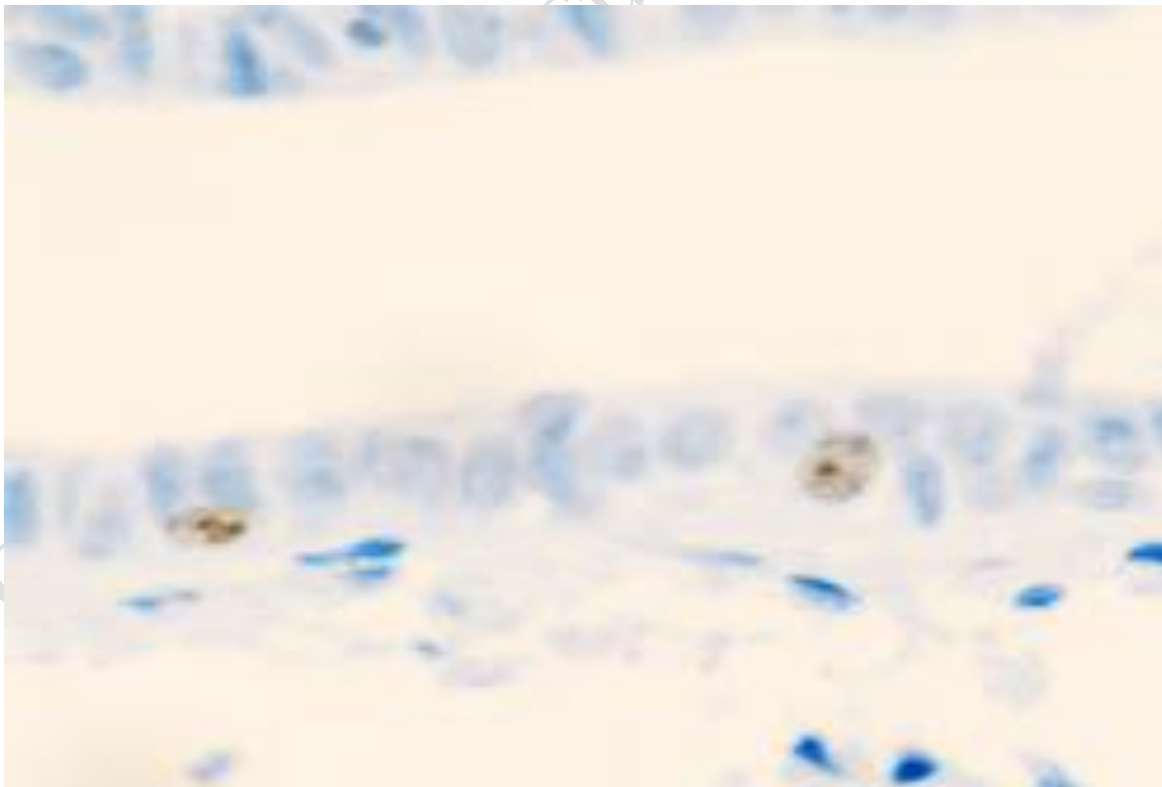


Fig. 2. 63-year-old woman, localization of Ki67 gene protein with low expression (dim brown markers in image) in the structures of the cervical mucosa in normal postmenopausal period (Immunohistochemistry)

with hematoxylin, 400×)

Thus, we observed that in postmenopausal women there is an increase in progesterone receptors, a decrease in estrogen levels is associated with a decrease in estrogen receptors and a sharp decrease in proliferative activity in the epithelial lamina of the CM (Fig. 3).

The number of Ki67-positive cells in the pathologic course during the postmenopausal period increases to a greater extent in the exocervical CM compared to the norm, which can be attributed to pathogen contamination and adaptive sloughing of the epithelium on the epithelial surface, these data for norm and pathology are presented in Tables 1 and 2.

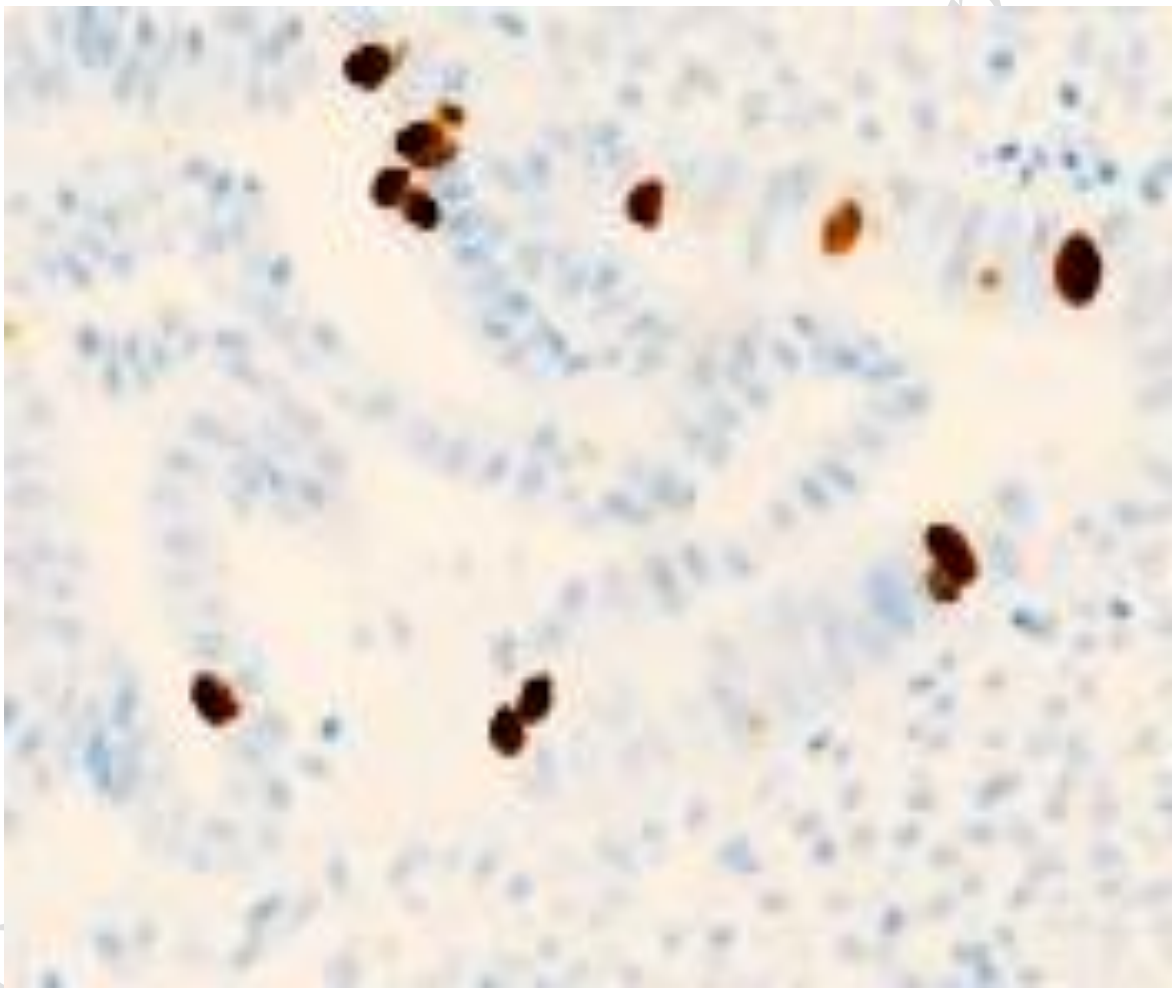


Fig. 3. Localization of the Ki67 gene protein with high expression (bright brown markers in image) in the structures of the cervical mucosa in the presence of polyps in the cervical mucosa (Immunohistochemistry, 200×)

When statistical analysis was performed to compare the average using Student's test and the difference in

the distribution of the data using the Wilcoxon test, it was determined that there were statistically significant differences in the exocervix in any period (average over the next 5 years after the onset of expression at 2.34% at normal vs. 2.78% at pathology), and in the transformation zone (2.4% at normal vs. 3.2% at pathology) and endocervix (1.8% at normal vs. 2.5% at pathology) in the first year of postmenopause as a function of PMP normality (p-value < 0.01) and increased mean Ki-67 expression level at pathology; no statistically significant differences were observed in the transformation zone and endocervix in subsequent years after the onset of postmenopause with respect to the progression of PMP.

Table 1. Evaluation of the location and quantification of Ki-67-positive cell activity in the CM of patients*

CM structures control	Average Ki-67 gene activity in normal postmenopausal period (number of mitoses per 100 cells in %)					Total average for 5 years
	1 year PMP	2 year PMP	3 year PMP	4 year PMP	5 year PMP	
Exocervix	3.2	2.4	2	2.9	1.2	2.34
Transformation zone	2.4	2.4	2.1	2.6	1.1	2.12
Endocervix	1.8	2.4	1.9	1.5	1.1	1.74

* CM – cervical mucosa, PMP – postmenopausal period

Table 2. Evaluation of location and quantitative characterization of Ki-67 - positive cells activity in CM of patients with pathological course of postmenopausal period*

CM structures in the observation group	Average activity of the Ki-67 gene in the pathological course of the postmenopausal period (number of mitoses per 100 cells in %)					Total average for 5 years
	1 year PMP	2 year PMP	3 year PMP	4 year PMP	5 year PMP	
Exocervix	4.2	2.9	2.5	2.6	1.7	2.78
Transformation zone	3.2	2.5	2.2	1.8	1.3	2.2
Endocervix	2.5	2.4	1.9	1.6	0.8	1.84

* CM – cervical mucosa, PMP – postmenopausal period

Discussion

The observed variations in the activity of the Ki-67 gene in different sections of the CM reveal complex

patterns of regenerative potential during the postmenopausal period. Our findings contribute novel insights into the dynamic nature of cervical tissue regeneration, expanding the existing literature.^{8,9}

A particularly notable result is the significantly higher activity of the Ki-67 gene observed in the exocervix, corroborating and extending previous research that reported elevated regenerative potential in this outermost cervical layer.^{6,7} This robust regenerative activity, marked by increased cell proliferation, highlights the exocervix's essential role as a protective barrier against environmental challenges, suggesting that constant exposure to external factors requires active tissue renewal and repair. In contrast, other studies have indicated no significant decrease in Ki-67 gene activity in the transformation zone compared to the exocervix.¹²

This discrepancy could arise from differences in study populations, methodologies, or age group definitions. Our findings suggest a nuanced transition in the balance between cell proliferation and turnover as the cervical mucosa progresses from the exocervix to the transformation zone. More research on hormonal signaling, microenvironmental factors, and molecular mechanisms specific to this region is needed to clarify these differences.

Our findings regarding the endocervix, which exhibited the lowest Ki-67 gene activity, align with previous data indicating a reduced regenerative potential in this innermost cervical layer.¹⁶ This diminished proliferative activity offers valuable insights into the cellular mechanisms associated with age-related changes in cervical tissues. Investigating the molecular pathways that regulate the endocervix's regenerative potential could reveal novel therapeutic targets for age-related cervical health issues, underscoring the importance of our study in advancing a broader scientific understanding of postmenopausal cervical dynamics.

HPV infection, particularly with high-risk strains such as HPV-16 and HPV-18, significantly affects the regenerative and transformation mechanisms of the endocervix by disrupting normal cellular processes. The viral oncoproteins E6 and E7 inactivate tumor suppressor proteins p53 and Rb, respectively, leading to uncontrolled cell proliferation and impaired apoptosis. This interference alters the regenerative potential of endocervical cells, initially increasing proliferation but eventually causing genomic instability. Furthermore, HPV-induced changes can promote the transformation of normal squamous epithelium into precancerous lesions, increasing the risk of cervical cancer. Studies have shown that HPV infection can also result in chronic inflammation, further exacerbating cellular damage and dysregulation.¹⁴ Additionally, the integration of HPV DNA into the host genome can disrupt key regulatory regions and contribute to the carcinogenic process.¹⁵ The persistent infection and the resulting cell changes highlight the critical need for monitoring and managing HPV infections to mitigate their impact on cervical health.

The comparative analysis with existing research offering new perspectives on the regenerative potential of various cervical mucosal sections during the postmenopausal period. These insights contribute to a more comprehensive understanding of age-related changes in cervical tissues and establish a foundation for

potential therapeutic interventions. Notably, the ectocervix's low Ki-67 gene activity suggests a relatively diminished regenerative capacity, likely due to natural aging, hormonal changes, or other postmenopausal physiological factors. This observation highlights the cellular mechanisms behind age-related changes in cervical tissues. Further exploration of the molecular pathways involved could lead to novel therapeutic approaches for managing age-related cervical health issues.

Conclusion

In this study, we elucidated the regenerative potential of distinct sections of the CM by examining Ki-67 gene activity across PMP age groups. The findings reveal a nuanced age-related dynamic in the proliferative activity of cervical mucosal epithelial cells, aligning with the research objectives.

Our investigation demonstrated significantly higher Ki-67 gene activity in the exocervix, indicating robust regenerative potential and active tissue renewal and repair mechanisms. This emphasizes the exocervix's crucial role in maintaining a healthy cervical barrier, especially against environmental challenges.

Conversely, the transformation zone showed a notable decrease in Ki-67 gene activity compared to the exocervix, suggesting a shift in the balance between cell proliferation and turnover as the mucosa transitions from the exocervix to the transformation zone. This dynamic may be influenced by hormonal signaling, microenvironmental factors, or other molecular mechanisms specific to this region.

Additionally, the study revealed the endocervix's lowest Ki-67 gene activity values, indicating a relatively diminished regenerative potential in this innermost layer. This observation provides critical insights into the cellular mechanisms underlying age-related changes in cervical tissues, aligning with our objective to explore the postmenopausal period's impact comprehensively.

The practical significance of these findings lies in their potential to inform tailored medical approaches for postmenopausal women, enabling improved prevention and monitoring strategies for cervical conditions.

Understanding the regenerative dynamics of different cervical sections contributes to the broader landscape of women's health, guiding healthcare professionals in addressing age-specific concerns. However, this study has limitations, since it was performed in a single medical institution, and there was no more complete information about the patients' medical history and their further treatment.

Looking forward, future research endeavors should delve deeper into the molecular pathways governing the regenerative potential of each cervical section. Investigating specific factors influencing Ki67 gene activity and exploring potential therapeutic interventions based on these insights could enhance our ability to address age-related cervical health issues more effectively. Additionally, expanding the study to include a broader demographic and considering longitudinal assessments could provide a more comprehensive understanding of the age-related dynamics in cervical mucosal epitheliocytes.

In conclusion, our study advances the understanding of age-related changes in cervical tissues, providing valuable insights into the regenerative potential of different cervical mucosal sections. These findings

contribute to the evolving field of women's health, with implications for personalized medical approaches and avenues for further in-depth exploration.

Acknowledgements

The study was supported by the FEFU's program Priority-2030 and federal program Student startup.

Declarations

Funding

The study was supported by the FEFU's program Priority-2030 and federal program Student startup.

Author contributions

Conceptualization, D.P.P. and G.V.R.; Methodology, D.P.P. and B.O.S.; Software, B.O.S.; Formal Analysis, B.O.S., and D.P.P. and I.V.R.; Investigation, I.P.K. and S.N.S.; Writing – Original Draft Preparation, B.O.S., D.P.P. and G.V.R.; Writing – Review & Editing, I.V.R., S.N.S. and V.V.U.; Visualization, D.P.P. and B.O.S.; Supervision, K.V.S. and M.B.K.

Conflicts of interest

The authors have no conflicts of interest to declare.

Data availability

Data not available due to legal restrictions.

Ethics approval

The research was approved by the Local Ethics Committee of Far Eastern Federal University, Vladivostok in the protocol No. 6 dated April 19, 2023.

References

1. Fedorova AI, Novikov EI, Grin EA, et al. The role of chronic cervicitis and disorders of local immunity of the cervix in the etiology of undeveloped pregnancy. *Gynecology*. 2021;23(6):509-515. doi 10.26442/20795696.2021.6.201259
2. Shakhabova HR, Palieva NV, Petrov YA, et al. Inflammation of the uterus and reproductive disorders in women. *Chief physician of the South of Russia*. 2022;2(83):17-21.
3. Barrios De Tomasi J, Opata MM, Mowa CN. Immunity in the Cervix: Interphase between Immune and Cervical Epithelial Cells. *J Immunol Res*. 2019;2019:7693183. doi: 10.1155/2019/7693183
4. Li C, Hua K. Dissecting the Single-Cell Transcriptome Network of Immune Environment

- Underlying Cervical Premalignant Lesion, Cervical Cancer and Metastatic Lymph Nodes. *Front Immunol.* 2022;13:897366. doi: 10.3389/fimmu.2022.897366
5. Kaliterna V, Barisic Z. Genital human papillomavirus infections. *Front Biosci (Landmark Ed).* 2018;23(9):1587-1611. doi: 10.2741/4662
 6. Tang J, Li M, Zhao C, et al. Therapeutic DNA Vaccines against HPV-Related Malignancies: Promising Leads from Clinical Trials. *Viruses.* 2022;14(2):239. doi:10.3390/v14020239
 7. Wahid M, Dar SA, Jawed A, et al. Microbes in gynecologic cancers: Causes or consequences and therapeutic potential. *Semin Cancer Biol.* 2022;86(2):1179-1189. doi: 10.1016/j.semcancer.2021.07.013
 8. Demura TA, Kogan EA, Kossovich YM, et al. Morphological and molecular criteria of endometrial receptivity disorders in patients with infertility associated with chronic endometritis. *Archives of Obstetrics and Gynecology.* 2018;5(1):19-25. doi: 10.18821/2313-8726-2018-5-1-19-25
 9. Ryzhkov VV, Khazhbiev AA, Derevyanko TI, et al. Some modern aspects of the clinical course, diagnosis and treatment of inflammatory diseases of the urogenital system of women. *Tavrisheskiy medico-biological bulletin.* 2017;20(2):135-139.
 10. Lee SJ, Yang A, Wu TC, et al. Immunotherapy for human papillomavirus-associated disease and cervical cancer: review of clinical and translational research. *J Gynecol Oncol.* 2016;27(5):e51. doi: 10.3802/jgo.2016.27.e51
 11. Xu XQ, Guo L, Wang X, et al. Human Cervical Epithelial Cells Release Antiviral Factors and Inhibit HIV Replication in Macrophages. *J Innate Immun.* 2019;11(1):29-40. doi: 10.1159/000490586
 12. Zhang J, Meng S, Zhang X, et al. Infiltration Patterns of Cervical Epithelial Microenvironment Cells During Carcinogenesis. *Front Immunol.* 2022;13:888176. doi: 10.3389/fimmu.2022.888176
 13. Goldštajn MŠ, Mikuš M, Ferrari FA, et al. Effects of transdermal versus oral hormone replacement therapy in postmenopause: a systematic review. *Arch Gynecol Obstet.* 2023;307(6):1727-1745. doi: 10.1007/s00404-022-06647-5
 14. Budhwani M, Lukowski SW, Porceddu SV, et al. Dysregulation of Stemness Pathways in HPV Mediated Cervical Malignant Transformation Identifies Potential Oncotherapy Targets. *Front Cell Infect Microbiol.* 2020;10:307. doi: 10.3389/fcimb.2020.00307
 15. Ferrari FA, Magni F, Bosco M, et al. The Role of Micronutrients in Human Papillomavirus Infection, Cervical Dysplasia, and Neoplasm. *Healthcare (Basel).* 2023;11(11):1652. doi: 10.3390/healthcare11111652
 16. Jackson R, Lukacs JD, Zehbe I. The Potentials and Pitfalls of a Human Cervical Organoid Model Including Langerhans Cells. *Viruses.* 2020;12(12):1375. doi: 10.3390/v12121375
 17. Reva I, Shcheglov B, Puga D, et al. Quantitative dynamics of immunocompetent cells in the

structure of epithelial differons of the cervix in women of older age groups. *Higher School: Scientific Research: Proceedings of the Interuniversity International Congress, Moscow.* 2023;2:33-37.

ONLINE FIRST Eur J Clin Exp Med