



REVIEW PAPER

Jan Frańczak^{1(ABCDG)}, Paweł Pakla^{1(ABC)}, Robert Brodowski^{1(ABCG)}, Wojciech Stopyra^{1(ABCFG)},
Danuta Burdzy^{3(BG)}, Bogumił Lewandowski^{ID 1,2 (ABFG)}

Review of surgical techniques for the reconstruction of the maxillofacial region used in the Department of Maxillo-Facial Surgery in Rzeszów

¹ Clinical Department of Maxillo-Facial Surgery, Frederic Chopin Provincial Specialist Hospital in Rzeszów

² Institute of Emergency Medicine, Faculty of Medicine, the University of Rzeszów

³ Private cosmetology clinic in Rzeszów

ABSTRACT

Postoperative reconstruction of tissue loss within the head and neck after extensive resections due to malignant neoplasms or traumas has always been a challenge for maxillo-facial surgeons or ENT physicians. Due to the complex anatomical structure of the head and neck region, every patient requires an individual approach and there is no standard method of management appropriate for all patients. The number of patients treated for malignancy is increasing year by year. The possibility of performing extensive resections in the head and neck region are conditioned by appropriate reconstruction.

Aim. The aim of the paper is to present the reconstructive methods used in the Clinical Department of Maxillofacial Surgery, F. Chopin Hospital No. 1 in Rzeszów. A short review of the most commonly used flaps is presented, taking into account their advantages, disadvantages and surgical technique in terms of their usefulness in daily clinical practice.

Keywords. reconstructive surgery, microsurgery, surgical flaps, cancer of head and neck

Introduction

Year by year, an increase in the number of serious injuries associated with damage or loss of tissue following extensive oncological surgery is observed resulting in searches for new methods of reconstruction. Reconstructive methods known for centuries are still used in modern clinical practice, but new methods are still being sought, as evidenced by the development of surgical techniques and transplant surgery.

Reconstruction of head and neck tissue defects caused by traumas or extensive surgery of malignant tumours in this area is a significant challenge for surgeons with knowledge and skills in reconstructive surgery and modern reconstruction techniques. Understanding topographic and functional anatomy and physiology and connections with head and neck pathologies provided researchers with the opportunity to develop state-of-the-art surgical techniques to help

Corresponding author: Jan Frańczak, e-mail: janek.franczak@gmail.com

Participation of co-authors: A – Author of the concept and objectives of paper; B – collection of data; C – implementation of research; D – elaborate, analysis and interpretation of data; E – statistical analysis; F – preparation of a manuscript; G – working out the literature; H – obtaining funds

Received: 07.07.2017 | Accepted: 19.08.2017

Publication date: September 2017

patients recover, return to their normal lives and function in family and social life. Advances in reconstructive surgery ensure reconstruction of lost tissue with previously prepared autograft transplants, flaps, and various implants that allow reconstruction with a tissue block best suited to the structure and volume of a given defect or deformity.

Different, often simple surgical techniques i.e. free skin grafts or flaps adjacent to lost tissues and organs have been used in the reconstructive surgery of maxillofacial region for centuries. The oldest references present the experiences of Indians 3–4,000 years BC, who already at that time presented a high level of reconstructive surgery, especially in the reconstruction of the nose. The interest in reconstructive surgery was spread probably by Arabs from India through Egypt to Europe. In the Middle Ages, the interest in reconstructive surgery was reduced, only the great battles of the nineteenth century and the first and second World War became an experimental training ground for reconstructive surgery. Massive and extensive damage combined with loss and the amputation of tissues and organs forced the necessity of searching for reconstruction solutions and progress in this field of surgery.

The Russian surgeon Filatov introduced in 1916 a rolled up flap formed with abdominal tissues which became the breakthrough in reconstructive surgery. A cylindrical flap was independently developed and described in 1917 by the English surgeon Gilles. In Eastern Europe, this flap is referred to as Filatov's flap, while in the Anglo-Saxon countries as Gilles's flap. This flap allowed for many decades to reconstruct extensive defects even in areas of the body remote to the donor site.

Modern reconstructive techniques also allow for transfer of tissues from distant regions of the body to the recipient area as pedicled or free flaps anastomosed with the recipient site using microsurgical techniques. The 1970s and 1980s were characterized by a flourishing of new flap techniques. In 1978, Yang introduced a radial forearm flap, in 1984 Song et al. developed the anterolateral thigh flap and in 1989 Hidalgo developed a fibula free flap.¹⁻³ Knowledge of flap techniques gained during the past four decades using microsurgical anastomoses and technological advances in medicine have contributed to a significant improvement in the effectiveness of reconstructing defects with free flaps. Nowadays, vascularized grafts may contain soft tissues (skin, fascia, muscle) and bone. Each of the mentioned tissues can be used as a single graft, e.g. cutaneous, muscular, bone flap or as a flap composed of several tissues, such as fascial-cutaneous and osteo-myo-cutaneous flaps. It is possible to combine two or more independent flaps as so called chimeric flaps, which additionally increase the reconstructive potential.⁴

Characteristics of selected methods of reconstruction

Pedicled flaps

Sternocleidomastoid (SCM) flap

The first reconstruction using SCM muscle was described by Jianu in 1908.⁵ The SCM flap was used to reconstruct facial expressions in patients with facial nerve damage. Since 1955, when Owens first applied a myo-cutaneous flap based on SCM, numerous modifications have been made regarding the vascularisation, the location and length of the pedicle.⁶ In 1970, the first flap was described, which included a clavicular fragment and was used to reconstruct the loss in the mandibular shaft resulting from the surgical excision of a malignant tumour.

SCM muscle along with the platysma belongs to the superficial muscles of the neck. The name of the muscle is derived from the insertions. The origin of the muscle are two heads attaching to the sternal manubrium and the sternal end of the clavicle. The distal insertion is the surface of the mastoid process of the temporal bone and the superior nuchal line.⁷

Due to the innervation of the flap by the external branch of the accessory nerve (XI) and preserving SCM muscle function, it was initially used to reconstruct the tongue after glossectomy, lip reconstruction and the bottom of the oral cavity. Poor vascularization of this flap, which in the upper part is supplied by the occipital artery and in the lower by inferior thyroid artery and the branches of auricularis posterior artery, limited its practical use. According to the Mathes and Nahai classification, the flap has a type II vascularization.⁸

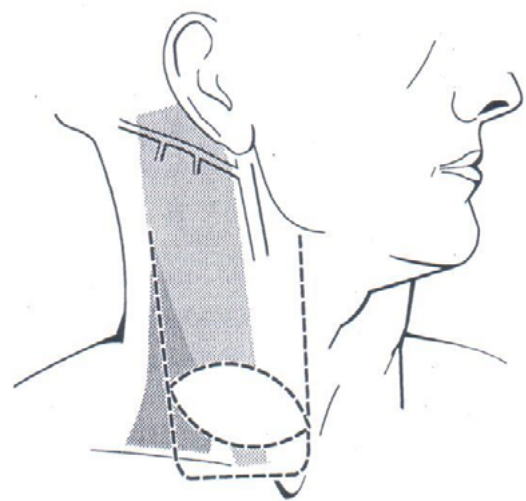


Figure 1. A pattern of SCM flap

In 1994, a study was conducted describing 120 patients with SCM flap. Total flap necrosis occurred in 7.3% of patients, while superficial skin necrosis in 22.7%. Fistulas of the oral cavity and neck were reported

in 11.8% of patients. The authors highlighted more frequent necrotic lesions in patients previously irradiated.⁹

Restrictions in using this flap are due to i.e. the size of myo-cutaneous island, closeness of cervical lymph nodes and internal jugular vein as potential lymph pathway from primary lesion, which limit the oncological purity of surgery, poor vascularisation of the type II lymph nodes, and the harmful effect of radiotherapy on its vascularization.

SCM flaps were mainly used to reconstruct small tissue defects following the removal of malignant neoplasms of the retromandibular triangle, lower gingiva, and the bottom of the oral cavity.

Deltoid-pectoral flap

In 1965, Bakamjian described a cutaneous flap with axial arterial vascularisation from intercostal arteries 2 to 4. In the 1960s it was the most commonly used flap to reconstruct neck tissue and the lower face defects. Since the 1970s, it has been gradually replaced by myocutaneous flap and free tissue grafts with micro-surgical anastomosis. Currently, the range of indications for the use of the deltoid-pectoral flap has been significantly reduced, as more beneficial reconstructive methods are more suitable in most cases.¹⁰ Since the beginning of the use of the deltoid-pectoral flap, many modifications have been made, with the most research being devoted to the technique of flap elongation. In 1974, Harii presented the deltoid-pectoral flap as a free microsurgical flap, but due to the short pedicle and difficulty in the recipient site supply, it was not the most commonly used solution.¹¹ The most common indication for the deltoid-pectoral flap is currently the large tissue defects in the lower floor of the face, in cases where there are contraindications to the use of microsurgical techniques.

The advantages of Bakamjian's flap are its good vascularization, adequate size and great flap vitality, the ability to connect with the great pectoral muscle flap. The most common complication in the flap is necrosis of its distal part. Kirkby observed total necrosis of the flap in 26% of the patients treated.¹⁰ In other studies, the incidence ranged from 9 to 16%.^{12,13} The greatest drawback of the deltoid-pectoral flap is the need for multi-stage treatment. In the first stage, flap needs to be formed and grafted in the donation site. About 4 weeks after the revascularisation of the displaced flap occurred, it is necessary to cut off its pedicle. The transplant site is covered by a free skin graft.

Myocutaneous flap of the pectoralis major

The theoretical bases of the pectoralis major flap were described for the first time by Pickerel in 1947.¹⁴ While in the late 1970s, Arriyan and Cuono introduced it in reconstruction of tissue defects in the head and neck. The

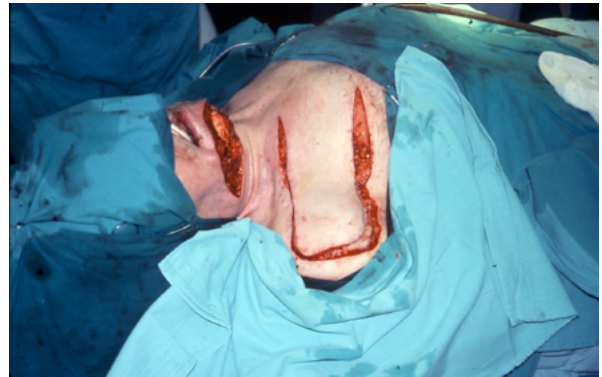


Figure 2. Range of flap preparation

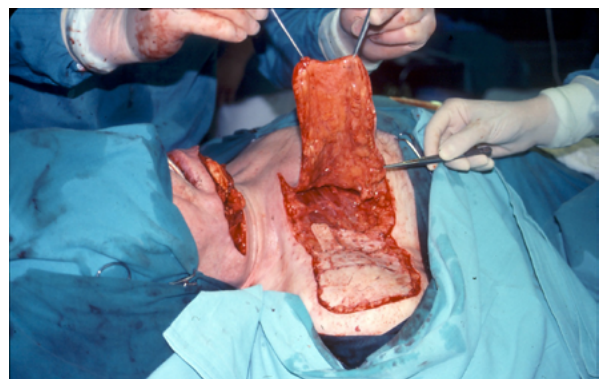


Figure 3. The deltoid-pectoral flap is dissected and lifted into recipient site

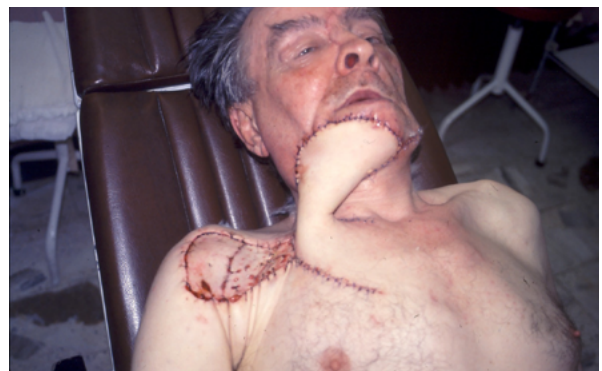

Figure 4. First stage of treatment with a deltoid-pectoral flap grafted into the receipt site

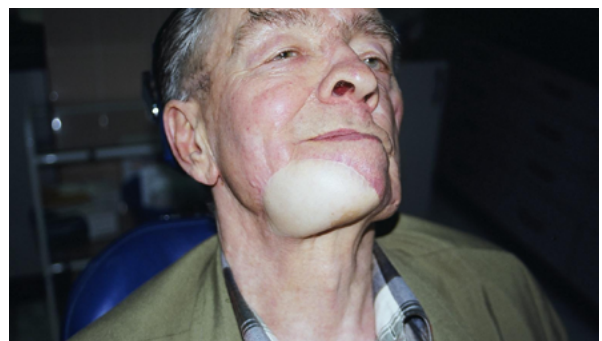

Figure 5. The final result of the treatment with a deltoid-pectoral flap

technique of reconstruction with the pectoralis major has become one of the most basic and most often applied in reconstructions of defects within the head and neck.

Pectoralis major is a triangular muscle belonging to the superficial muscles of the chest. Its superior origin is at the medial part of the clavicle, the anterior part of the sternum and the cartilage of the ribs I-VI, anterior lamina of rectus sheath, laterally on the crest of the greater tuberosity of the humerus.⁷

Classically, the myocutaneous flap consists of the cutaneous island and a part of the pectoralis major. It is possible to enrich the flap with a piece of rib to reconstruct bone defects. The flap is grafted in the orofacial region with muscular pedicle under the skin of the neck.

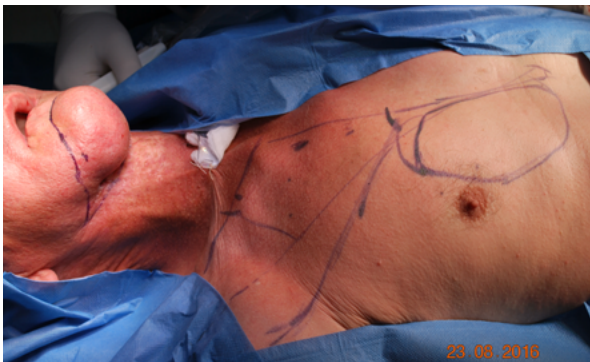

Figure 6. Planned range of pectoralis flap dissection

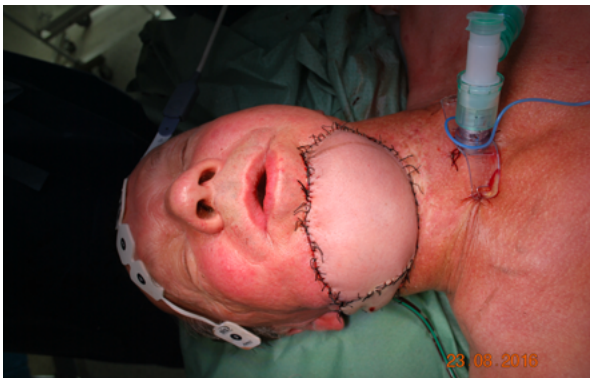

Figure 7. Status post flap transplant in the chin area

Flap vascularisation mainly consists of: thoracoacromial artery, branches of internal thoracic artery and lateral thoracic artery, vascularisation is defined as type V according to Mathes and Nahai. This flap is supplied by C5–C7 lateral thoracic nerve and the medial thoracic nerve C8, Th1. Axial muscle vascularisation and perforating branches which supply underlying skin allow rapid healing of the rotated flap even in the previously irradiated or infected field. Since its first description, many modifications, improvements and extensions of clinical indications have been made. Elongated flap or a flap with elongated external pedicle have been used

to reconstruct deficits in the upper face. On the other hand, a double-sided flap covered on the internal part with a free skin graft or a sandwich flap are useful for reconstruction of the full thickness of the cheek.¹⁵ The donor site on the chest can be closed initially. Pectoral flaps are usually well tolerated, in a variety of studies total flap necrosis have occurred in 1%, 1.5%, 3%, 7% of the cases.^{16–19} Partial necrosis was much more common – in 14% of patients over 50% of the flap was subject to necrosis in Schusterman's studies.²⁰

The advantages of the pectoralis major flap is its size, strong axial blood supply, the possibility of simultaneous use with other flaps and a small number of complications in the donor site. This flap also has disadvantages: in men the hairy part of the flap is inserted into the mouth cavity, different coloration than the skin of the face, postoperative scars and deformation of the chest and breast in women, loss of respiratory function, especially with simultaneous damage to the XI nerve.^{21,22}

Free forearm flap

The cutaneo-fascial flap supplied by the radial artery often referred to as the Chinese flap, it was first described in 1981 by Yang.¹ The radial flap is a thin plastic flap that is perfect for reconstructing soft tissue loss in the mouth and throat. In addition, it is possible to enrich it with a fragment of radial bone, tendon, radio-brachial muscles and nerve fragments, which enhances its benefits.²³ Reconstructing the sensory nerve allows much faster and better rehabilitation of speech, swallowing and chewing. The major disadvantages of this flap are partial limitation of the upper limb function, the necessity of taking free skin grafts to provide the receiving place and the possibility of pathological fractures after the grafting from the radial bone. The arterial vascularization originates from the radial artery, venous drainage is done via the radius vein or two veins that accompany the radial artery.¹ Before the formation of the flap, an Allen test should be performed to assess the function of the superficial artery, which provides good vascularization of the hand after radial artery excision. Allen's test consists of simultaneous compression of the radial and ulnar arteries, after pressure release on the ulnar artery, the circulation should return in the whole hand.²⁴

At the recipient place of the arterial anastomosis is performed, usually end to end type, in the first place with neck vessels: facial artery, laryngeal artery. Depending on the vein diameter, end to end anastomosis is performed, e.g. with facial vein or end to side if there are large differences in the diameter of the vein, e.g. internal jugular vein. Planning and preparation of the flap, anastomosis and grafted flap in the recipient site are presented in the figures.

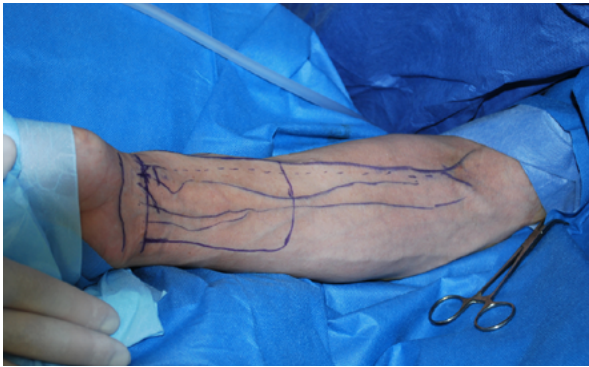

Figure 8. Range of flap dissection

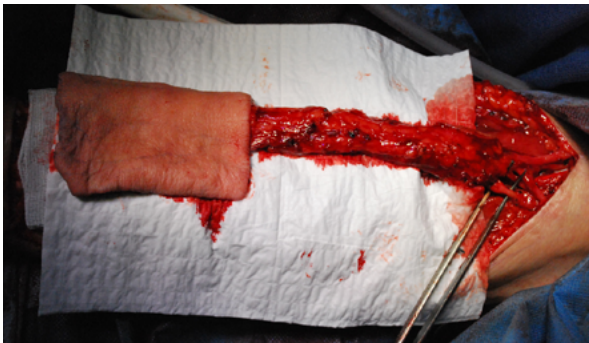


Figure 9. Dissected Chinese flap with marked radial artery on the tweezers

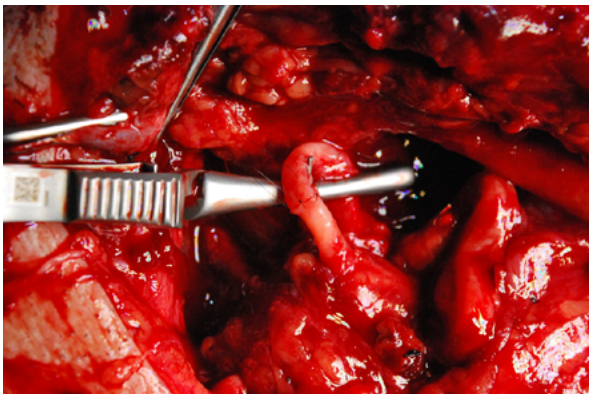


Figure 10. End to end anastomosis of the radial and facial arteries

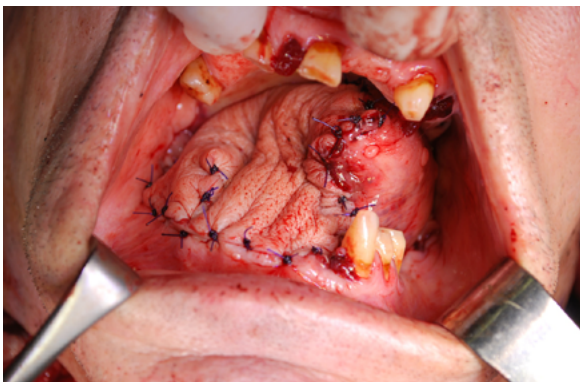


Figure 11. Grafted flap after hemiglossectomy with the resection of the bottom of the oral cavity

Conclusion

The choice of the right reconstructive method should be done individually taking into account the location, volume and structure of the tissue defect, donor sequelae and surgeon experience. Modern surgical techniques and technological advances have contributed to a significant improvement in the effectiveness of tissue reconstruction in patients after extensive resections in the head and neck. The use of microvascular free flaps is an effective and versatile reconstructive method in head and neck surgery.

References

1. Yang G, Chen B, Gao Y, et al. Forearm free skin flap transplantation. *Chin Med J*. 1981;61:139.
2. Song YG, Chen GZ, Song YL. The free thigh flap: a new free flap concept based on septocutaneous artery. *Br J Plast Surg*. 1984;37:149-159.
3. Hidalgo D. Fibula free flap: a new method of mandible reconstruction. *Plast Reconstr Surg*. 1989;84:71.
4. Szwedowicz P, Bruzgielewicz A, Niemczyk K, Brozyna B, Jaworowski J, Osuch-Wójcikiewicz E. Zastosowanie mikronaczyniowych wolnych płatów powięziowo-skórnych i mięśniowo-skórnych w chirurgii głowy i szyi. *Otolaryngol Pol*. 2011;65(5a):53-59.
5. Jianu J. Paralizie faciale dupa extriparea unei tumori a parotidei trata operatia dlui gomuoae. *Bull Mem Soc Clin Bucharest*. 1908:22.
6. Owens N. A compound neck pedicle designed for the repair of massive facial defects: formation, development and application. *Plast Reconstr Surg*. 1955;15:369-389.
7. Bochenek A, Reicher M. Anatomia człowieka. Warszawa, PZWL; 2007.
8. Larson DL, Goepfert H. Limitations of the sternocleidomastoid musculocutaneous flap in head and neck cancer reconstruction. *Plast Reconstr Surg*. 1982;3:328-335.
9. Sebastian P, Cherian T, Ahamed I, Jayakumar K, Sivaramkrishnan P. The sternomastoid island myocutaneous flap for oral cancer reconstruction. *Arch Otolaryngol Head Neck Surg*. 1994; 120:6.
10. Kirkby B, Krag C, Siemssen O. Experience with the deltopectoral flap. *Scand J Plast Reconstr Surg Hand Surg*. 1980;14:151.
11. Harii K, Ohmori K, Ohmori S. Free deltopectoral skin flaps. *Br J Plast Surg*. 1974;27:231.
12. Bakamjian VY, Long M, Rigg B. Experience with the medially based deltopectoral flap in reconstructive surgery of the head and neck. *Br J Plast Surg*. 1971; 24:174.
13. Park J, Sako K, Marchette F. Reconstructive experience with the medially based deltopectoral flap. *Am J Surg*. 1974; 128:548.
14. Pickerel KL, Baker HM, Collins JP. Reconstructive surgery of the chest wall. *Surg Gynecol Obstet*. 1947;84:465.
15. Russel RC, Feller AM, Elliot LF, Kucan JO, Zook EG. The extended pectoralis major myocutaneous flap: use and indications. *Plas Reconstr Surg*. 1991;88:814-823.

16. Ossof R, Wurster C, Berktold R, Krespi Y, Sisson G. Complications after pectoralis major myocutaneous flap reconstruction of head and neck defects. *Arch Otolaryngol Head Neck Surg.* 1983;109:812.
17. Baek S, Lawson W, Biller HF. An analysis of 133 pectoralis major myocutaneous flaps. *Plast Reconstr Surg.* 1982; 69:460.
18. Shah JP, Haribhakti V, Loree TR, Sutaria P. Complications of the pectoralis major myocutaneous flap in head and neck reconstruction. *Am J Surg.* 1990;160:352-355.
19. Wilson J, Yiacaimettis A, O'Neill T. Some observations on 112 pectoralis major myocutaneous flaps. *Am J Surg.* 1984;147:273.
20. Schusterman M, Kroll S, Weber R, Byers R, Guillamondegui O, Goepfert H. Intraoral soft tissue reconstruction after cancer ablation: a compilation of the pectoralis major flap and the free radial forearm flap. *Am J Surg.* 1991;162:397.
21. Wanyura H, Kamiński A, Uliasz M, Stopa Z. Płat skórno-mięśniowy z mięśnia piersiowego większego do rekonstrukcji ubytków powstałych po usunięciu nowotworów złośliwych dolnego piętra twarzy. *Czas Stomatol.* 2006;7:473-490.
22. Jetton J. Powikłania przy stosowaniu wyspowego płata skórno-mięśniowego z mięśnia piersiowego większego. *Otolaryng Pol.* 1986;40(6):427-431.
23. Vaughan ED. The radial forearm free flap in orofacial reconstruction. *J Craniomaxillofac Surg.* 1990;18:2.
24. Timmons M. The vascular basis of radial forearm free flap. *Plast Reconstr Surg.* 1986;77:80.